

# Altered Retrobulbar Hemodynamics in Patients Who Have Transient Monocular Blindness Without Carotid Stenosis

A-Ching Chao, MD; Hung-Yi Hsu, MD, PhD; Chih-Ping Chung, MD; Yen-Yu Chen, MD;  
May-Yung Yen, MD; Weng-Jang Wong, MD; Han-Hwa Hu, MD

**Background and Purpose**—This study was to evaluate the retrobulbar hemodynamics in patients who have transient monocular blindness (TMB) without carotid stenosis.

**Methods**—Fifty-nine patients who have TMB without carotid stenosis were studied along with 59 age- and sex-matched controls. Color Doppler-imaging was used to study the retrobulbar hemodynamic by measuring the flow velocities (peak-systolic velocity, and end-diastolic velocity), vascular resistance indices (pulsatility index, and resistance index) in central retinal arteries, short posterior ciliary arteries, and ophthalmic arteries. The patients were divided into 2 groups according to the attack frequency: group 1 (occasional TMB, 2 or fewer attacks, 26 patients) and group 2 (frequent TMB, 3 or more attacks, 33 patients).

**Results**—The risk factors for atherosclerosis were similar between the cases and controls. The means of end-diastolic velocity were significantly lower in central retinal arteries and ophthalmic arteries, and the pulsatility index and resistance index were significantly higher in all the 3 retrobulbar vessels in TMB patients than for the controls. The differences between patients and controls were greater for the group-2 patients.

**Conclusion**—Patients who have TMB without carotid stenosis had altered retrobulbar hemodynamics with a generalized increase in vascular resistance in the retrobulbar arteries. The role of venous hypertension as an etiology needs further study. (*Stroke*. 2007;38:1377-1379.)

**Key Words:** color Doppler ■ retrobulbar vessel ■ transient monocular blindness ■ venous hypertension

The mechanism of visual loss is not clear in many patients with transient monocular blindness (TMB). Although the carotid arterial stenosis and other conditions associated with TMB have been reported,<sup>1</sup> still in ≈50% of patients no underlying cause can be demonstrated.<sup>2</sup> Postural change or exercise is a precipitating factor in 10% to 46% of some benign, recurrent TMB patients.<sup>3</sup> C. M. Fisher once speculated that mechanical factors are operative in these patients,<sup>4</sup> but this has never been proven. We hypothesize that if mechanical factors existed, these might be reflected in the changes of retrobulbar hemodynamics.

## Methods

We prospectively studied 105 consecutive patients who had experienced transient loss of vision in 1 eye that lasted <24 hours. All patients were examined by a neurologist and an ophthalmologist within 1 week of their last TMB attack. The study methodology of patient recruitment, the clinical characteristics, results of investigations, and patterns of visual loss in these patients have been reported elsewhere.<sup>2</sup> Fifty-nine of these 105 patients who had no carotid stenosis and no underlying problem related to TMB were included in this study. There were 59 healthy volunteers recruited for comparison.

All participants received Color Doppler-imaging examination of the orbital vessels using a computed sonography system with 7.5-MHz linear transducer (Acuson, Sequoia) by the same sonographer. The flow velocities (peak-systolic velocity, and end-diastolic velocity), vascular resistance indices (pulsatility index [PI] and resistance index [RI]) in ophthalmic arteries, short posterior ciliary artery, central retinal artery (CRA), central retinal vein, and superior ophthalmic vein were measured using the method as described in our previous study.<sup>5</sup> Patients were divided into 2 groups according to the attack frequency: those who had had 2 or fewer TMB attacks were classified as group 1 (occasional TMB, 26 patients) and those who had had 3 or more attacks as group 2 (frequent TMB, 33 patients). The Mann-Whitney *U* test was used to compare the affected eyes with controls and compare the healthy eyes with controls. Wilcoxon matched-pair signed-rank tests were used to compare the affected eye with the patient's healthy fellow eye.

## Results

Of the 59 patients, the mean age was 63.8±14.7 years old, with 24 females, and that of the controls was 65.0±11.0, with 24 females. There was no statistically significant difference in major vascular risk factors—such as age, sex, hypertension, diabetes, hyperlipidemia, previous stroke or transient ischemic attack, coronary artery diseases, smoking, migraine or

Received November 2, 2006; accepted November 15, 2006.

From the Department of Neurology (A.-C.C.), Kaohsiung Medical University and Hospital, Kaohsiung, Taiwan; Section of Neurology (H.-Y.H.), Department of Internal Medicine, Taichung Veterans General Hospital, Taichung, Taiwan; Section of Cerebrovascular Disease (C.-P.C., Y.-Y.C., W.-J.W., H.-H.H.), Neurological Institute, Taipei Veterans General Hospital, Taipei, Taiwan; Department of Ophthalmology (M.-Y.Y.), Taipei Veterans General Hospital, Taipei, Taiwan; and National Yang-Ming University. (H.-Y.H., C.-P.C., Y.-Y.C., H.-H.H., M.-Y.Y.), Taipei, Taiwan.

Correspondence to Han-Hwa Hu, MD, Professor of Neurology, Chief of Cerebrovascular Disease, Neurological Institute, Veterans General Hospital-Taipei, Taipei 112, Taiwan. E-mail hhu@vghtpe.gov.tw

© 2007 American Heart Association, Inc.

Stroke is available at <http://www.strokeaha.org>

DOI: 10.1161/01.STR.0000260188.51784.6e

The Resistance and Pulsatility Indices of Retrobulbar Arteries in Patients and Controls

	Controls, n=59	Occasional TMB, n=26 (Group 1)		Frequent TMB, n=33 (Group 2)	
		Affected Eye	Fellow Eye	Affected Eye	Fellow Eye
<b>RI</b>					
Central retinal artery	0.57±0.07	0.62±0.07	0.64±0.08	0.68±0.09	0.69±0.06
<i>P</i> value*		0.0396	0.0061	0.0001	0.0000
Posterior ciliary artery	0.58±0.08	0.60±0.09	0.65±0.08	0.63±0.06	0.63±0.07
<i>P</i> value*		0.4818	0.0122	0.0542	0.0617
Ophthalmic artery	0.69±0.09	0.74±0.06	0.74±0.08	0.76±0.06	0.76±0.05
<i>P</i> value*		0.0809	0.0976	0.0152	0.0131
<b>PI</b>					
Central retinal artery	0.96±0.24	1.08±0.20	1.15±0.24	1.29±0.29	1.29±0.21
<i>P</i> value*		0.1299	0.0229	0.0003	0.0001
Posterior ciliary artery	0.95±0.21	1.03±0.25	1.16±0.24	1.10±0.20	1.11±0.21
<i>P</i> value*		0.2939	0.0061	0.0369	0.0282
Ophthalmic artery	1.28±0.27	1.46±0.23	1.51±0.31	1.59±0.25	1.58±0.24
<i>P</i> value*		0.0456	0.0190	0.0009	0.0012

\**P* values are calculated from Mann-Whitney *U* test for affected and fellow eyes of each patient group vs controls.

body mass index—between the patients and the controls. The comparison between the affected eyes and controls, and between healthy eyes and controls were made with no statistical significance in the means of peak-systolic and end-diastolic velocity for all retrobulbar arteries. However, both the PI and RI were significantly higher in all retrobulbar arteries of the healthy and the affected eyes in patient groups, except for PI of central retinal artery and short posterior ciliary artery, RI of short posterior ciliary artery in group 1 patients (Table). Because there were no significant differences in all the flow velocities and the resistance indices of the affected eyes and their clinically healthy fellow eyes in either patient group, the averaged values of both eyes were compared between patients and the controls. The means of end-diastolic velocities of central retinal arteries and ophthalmic arteries were significantly lower in both patient-groups than in the controls respectively (Figure 1). The PI and RI of both patient-groups were significantly higher than those of the controls for all 3 retrobulbar vessels respectively (Figure 2). The differences of PI and RI between patients and controls are greater for the group 2 patients. Two patients in group 2 had had their TMB attacks during exercise, and 5 patients (one in group 1 and 4 in group 2) had had their TMB attacks during straining or bending over.

Discussion

This study is the first to demonstrate that patients of TMB without carotid stenosis have an increased PI and RI in the retrobulbar vessels. Considerable in vitro and in vivo evidence indicates that higher PI/RI and lower end-diastolic velocity are closely related to increased downstream vascular resistance from the point of Doppler-flow measurement.<sup>6</sup> Our data suggest a generalized increase in distal vascular resistance in the retrobulbar arterial circulation, both in the affected and the fellow eyes.

Increased PI and RI in retrobulbar arterial circulation have been reported in many ocular and extraocular disorders.<sup>7</sup> Our patients had detailed ophthalmic and physical examinations to rule out all possibilities of the literature reporting ocular and extraocular conditions that can cause an increased PI and RI. Moreover, the frequencies of systemic vascular risk factors in patient-groups were not different from those of controls, so there is no evidence supporting that accelerated arterial arteriosclerosis occurred in these patients. However, certain conditions, such as small arterial arteriosclerosis,

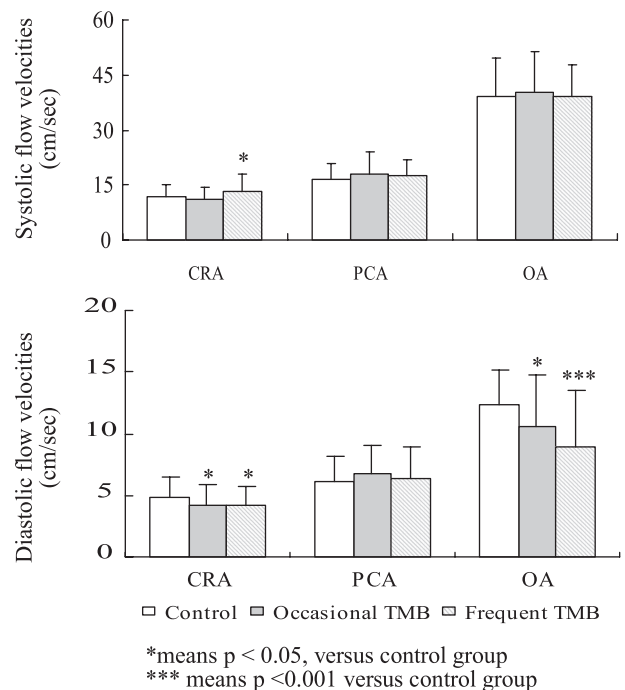
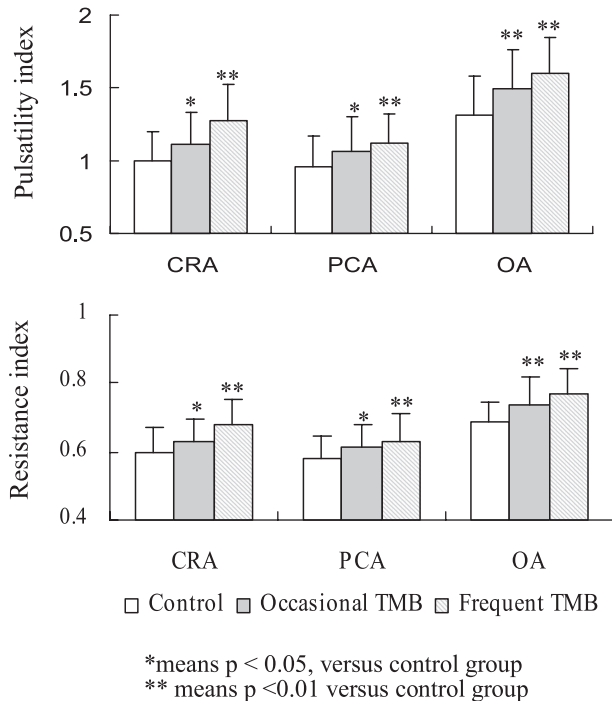


Figure 1. Comparisons of flow velocities in retrobulbar arteries between control and patient groups. CRA indicates central retinal artery; PCA, posterior ciliary artery; OA, ophthalmic artery.



**Figure 2.** Comparisons of Doppler velocity indices in retrobulbar arteries between control and patient groups.

increased vasoconstricting tone, and elevated ocular venous pressure, still could not be excluded.

Valsalva-like activity or exercise was a precipitating factor in 7 of our patients. It has been known that in the presence of venous outflow resistance, the Valsalva-like activities may allow retrograde transmission of high venous pressure from the thorax to the cerebral venous system, resulting in venous congestion and symptoms of cerebral ischemia.<sup>8</sup> Thus, in consistence with the Fisher speculation, the high vascular resistance in the retrobulbar arteries of our patients might be a result of the presence of venous outflow resistance and venous hypertension. The latter could transmit backwardly to the cavernous sinuses, then to the arterial sides. This mechanism might explain why both the affected eyes and the

clinically healthy eyes had higher retrobulbar vascular resistance without any plausible known local and systemic disorders. Moreover, the difference in the retrobulbar vascular resistance between patients and controls is greater in group 2 than in group 1 patients. This may further strengthen the role of the retrobulbar vascular resistance in the pathogenesis of the TMB.

### Summary

This study revealed a generalized high resistance in the retrobulbar hemodynamics in patients of TMB without carotid stenosis. Venous etiology might be a sensible hypothesis after exclusion of all other possible causes of generalized increased retrobulbar vascular resistance. Further studies to test whether venous hypertension plays a role in the pathogenesis of the TMB attack are awaited.

### Sources of Funding

This study was supported by grant NSC 94-2314-B-075-023 from National Science Council and grant VGHTPE-94-C1-290 from Veterans General Hospital-Taipei.

### Disclosures

None.

### References

1. Current management of amaurosis fugax. The amaurosis fugax study group. *Stroke*. 1990;21:201–208.
2. Hsu HY, Yang FY, Chao AC, Chen YY, Chung CP, Sheng WY, Hu HH. Distribution of carotid arterial lesions in Chinese patients with transient monocular blindness. *Stroke*. 2006;37:531–533.
3. Tomsak RL, Jergens PB. Benign recurrent transient monocular blindness: a possible variant of acephalgic migraine. *Headache*. 1987;27:66–69.
4. Fisher CM. 'Transient monocular blindness' versus 'amaurosis fugax'. *Neurology*. 1989;39:1622–1624.
5. Chen CC, Luo CL, Wang SJ, Chern CM, Fuh JL, Lin SH, Hu HH. Colour doppler imaging for diagnosis of intracranial hypotension. *Lancet*. 1999;354:826–829.
6. Spencer JA, Giussani DA, Moore PJ, Hanson MA. In vitro validation of doppler indices using blood and water. *J Ultrasound Med*. 1991;10:305–308.
7. Cheng CY, Liu CJ, Chiou HJ, Chou JC, Hsu WM, Liu JH. Color doppler imaging study of retrobulbar hemodynamics in chronic angle-closure glaucoma. *Ophthalmology*. 2001;108:1445–1451.
8. Chung CP, Hsu HY, Chao AC, Chang FC, Sheng WY, Hu HH. Detection of intracranial venous reflux in patents of transient global amnesia. *Neurology*. 2006;66:1873–1877.