

SAFETY OF PERFORMING PERCUTANEOUS DILATIONAL TRACHEOSTOMY IN PATIENTS WITH PREEXISTING BAROTRAUMA

Chau-Chyun Sheu, Jong-Rung Tsai, Meng-Hsuan Cheng, Inn-Wen Chong, Ming-Shyan Huang, and Jhi-Jhu Hwang

Division of Pulmonary and Critical Care Medicine, Department of Internal Medicine, Kaohsiung Medical University Hospital, Kaohsiung Medical University, Kaohsiung, Taiwan.

Since its introduction in 1985 by Ciaglia et al, percutaneous dilational tracheostomy (PDT) has gradually become the procedure of choice in establishing a long-term airway in many intensive care units (ICU). However, the safety of performing PDT in patients with barotrauma is still unknown and has never been reported. We present the case of a 35-year-old man with AIDS, who was admitted to our medical ICU for pneumonia and acute respiratory distress syndrome. He developed subcutaneous emphysema and pneumomediastinum as complications of mechanical ventilation. After stabilization of the barotrauma, he underwent PDT with the standard Ciaglia Blue Rhino technique. However, rapid and extensive progression of preexisting barotrauma occurred shortly after PDT. This severe complication was nearly fatal. The prolonged procedure during which the susceptible lung was exposed to longer duration of high airway pressure was thought to be the mechanism of rapid deterioration of the preexisting barotrauma. With aggressive supportive care, the patient survived. To prevent further deterioration of preexisting barotrauma during and after PDT in future cases, we propose some principles that should be strictly followed. Under administration of these principles, we safely performed PDT in another case with preexisting barotrauma 1 month later.

Key Words: barotrauma, percutaneous tracheostomy, pneumomediastinum, subcutaneous emphysema
(*Kaohsiung J Med Sci* 2006;22:570-4)

Since its introduction in 1985 by Ciaglia et al [1], percutaneous dilational tracheostomy (PDT) has been used extensively. Studies have shown PDT to be a cost-effective and safe alternative to surgical tracheostomy in critically ill patients [2-4]. It has become the procedure of choice in establishing a long-term airway in many institutions. With advances in techniques and

accumulation of experience, most of the perceived contraindications of PDT are no longer viewed as prohibitions, but as suggestions related to the skill level and training of the operator [5]. PDT has been reported to be a safe procedure in obese patients [6], patients with high positive end-expiratory pressure (PEEP) [7], patients with severe thrombocytopenia [8], and even patients with previous tracheostomy [9]. However, the safety of performing PDT in patients with barotrauma, i.e. subcutaneous emphysema, pneumothorax, or pneumomediastinum, is unknown and has never been reported.

Here, we present a patient who developed rapid and extensive progression of preexisting subcutaneous

Received: February 7, 2006

Accepted: June 9, 2006

Address correspondence and reprint requests to: Dr Jhi-Jhu Hwang, Division of Pulmonary and Critical Care Medicine, Department of Internal Medicine, Kaohsiung Medical University Hospital, 100 Tzyou 1st Road, Kaohsiung 807, Taiwan.
E-mail: jjhwang@ms4.hinet.net

emphysema and pneumomediastinum shortly after PDT. To prevent further deterioration of preexisting barotrauma during and after PDT in future cases, we propose some principles that should be strictly followed.

CASE PRESENTATION

A 35-year-old AIDS patient presented to our hospital with fever, productive cough, and progressive dyspnea for 1 week. A diagnosis of acute respiratory distress syndrome induced by pneumonia was made. He was intubated and received mechanical ventilation for severe hypoxemia on the 1st day of hospitalization, and remained on fraction of inspired oxygen (FiO_2) of greater than 0.6 during the first 3 weeks. On the 20th day of hospitalization, subcutaneous emphysema and pneumomediastinum occurred as complications of mechanical ventilation. Upon stabilization of his barotrauma, we decided to perform tracheostomy to establish a long-term airway for prolonged mechanical ventilation. On the 27th day of hospitalization, he was ventilated on FiO_2 of 0.4, and his barotrauma remained unchanged for several days according to the serial chest radiographs (Figure A).

The standard Ciaglia Blue Rhino technique [10] was performed under bronchoscopic guidance. During PDT, the patient was positioned supinely with pillows

placed under his shoulders to achieve neck hyperextension, and was ventilated with pressure control of 20 cmH_2O , respiratory rate of 24 breaths/minute, FiO_2 of 1.0, and PEEP of 5 cmH_2O . Fentanyl, midazolam, and atracrium were used for intravenous anesthesia. Vital signs were continuously monitored. After initial dilation with an introducer dilator, dilation of the tissue with a Blue Rhino dilator proved difficult. We used a curved hemostat twice to assist in dilating the subcutaneous tissue and anterior wall of the trachea. Although this technique required 8 minutes, from skin incision to the insertion of the tracheostomy tube, the procedure went smoothly with no prediction of any complication. Shortly after the procedure, subcutaneous emphysema over the neck and upper anterior chest wall was found, and extended rapidly to the whole body. Bedside chest radiography showed marked progression of the preexisting subcutaneous emphysema and pneumomediastinum (Figure B). Subsequently, severe respiratory acidosis and shock developed. Bronchoscopy was performed immediately, and we confirmed that the tracheostomy tube was in the correct position and the posterior tracheal wall was not injured. Therefore, we left the tracheostomy tube in place.

After 2 days of supportive care, the subcutaneous emphysema and pneumomediastinum began to resolve and totally disappeared on the chest radiographs taken 5 days after PDT. He was successfully

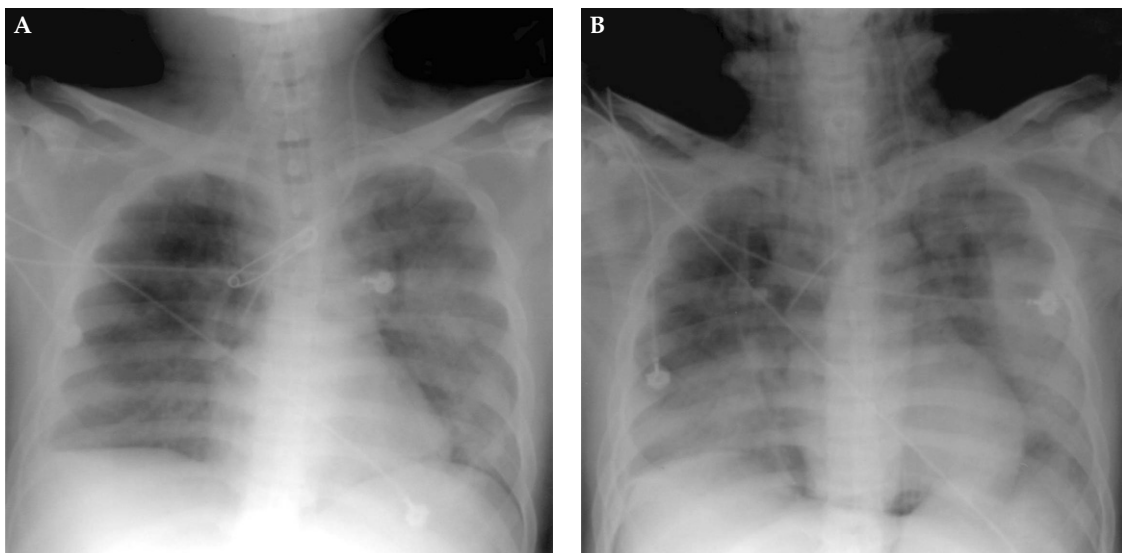


Figure. (A) Chest radiograph taken on the day before percutaneous dilational tracheostomy (PDT) showed barotrauma, presenting as subcutaneous emphysema and pneumomediastinum. (B) Chest radiograph taken immediately after PDT demonstrated marked progression of preexisting subcutaneous emphysema and pneumomediastinum.

weaned from the ventilator on the 51st day of ventilation and then decannulated.

DISCUSSION

PDT is now the standard procedure for tracheostomy in many ICUs. With the advances in techniques and accumulation of experience, the contraindications of PDT have become fewer. However, the safety of performing PDT in patients with barotrauma is unknown and has never been reported. To the best of our knowledge, this is the first article describing the safety of performing PDT in patients with preexisting barotrauma. We report a patient whose subcutaneous emphysema and pneumomediastinum rapidly deteriorated after the PDT procedure. This severe complication was nearly fatal.

Subcutaneous emphysema, pneumothorax, and pneumomediastinum are well known complications of PDT regardless of the techniques that are chosen. Fikkers et al [11] reviewed the literature and reported that the incidence of subcutaneous emphysema was 1.4%, and that of pneumothorax was 0.8%. Mechanisms involving the developments of these complications were also described, including damage to the anterior or posterior tracheal wall, false passage/paratracheal placement, dislocation of the cannula, complications related to a fenestrated cannula, and barotrauma. In our case, the postprocedure bronchoscopy confirmed that the tracheostomy tube was in the correct position, and that the peristomal and posterior tracheal mucosa was intact. We thought that the rapid deterioration of preexisting subcutaneous emphysema and pneumomediastinum was caused by barotrauma. The prolonged procedure caused the susceptible lung to be exposed to longer duration of high airway pressure, which was aggravated by the bronchoscope and Blue Rhino dilator in the airway.

Barotrauma is one of the major complications of mechanical ventilation. It is assumed that patients with the complication of barotrauma usually require a longer duration of mechanical ventilation and, therefore, tracheostomy is always indicated. However, the safety, optimal timing, and ideal procedure of tracheostomy for these patients are currently unclear and need further studies. Although most physicians tend to postpone tracheotomy in such high-risk patients, the benefits from tracheostomy may outweigh the risk

of the tracheostomy procedure and the complications of prolonged translaryngeal intubation.

To prevent further deterioration of preexisting barotrauma during and after PDT in future cases, we propose some principles that should be strictly followed: (1) *ventilate the patient with pressure control mode*. The plateau pressure should be kept at 30 cmH₂O or less. The respiratory rate should be set higher, up to 30 breaths/minute, to reduce hypoventilation during the procedure. (2) *Choose the most time-saving PDT procedure*. (3) *Operate with experienced personnel*. Since a learning curve exists in PDT [12], this high-risk group should be operated on by physicians with extensive experience. (4) *Limit the bronchoscopy time*. With the bronchoscope in the airway, the airway pressure rises and the tidal volume decreases. Bronchoscopy time can be reduced by way of intermittent use and by shortening the overall procedure time of PDT. (5) *Adequately sedate the patient postoperatively*. It is very important to maintain patient-ventilator synchronization and to avoid excessive cough during the postoperative period. Sedatives and analgesics should be administered with adequate dosage and tapered gradually with close clinical monitoring. Under administration of these principles, we safely performed PDT in another case with preexisting barotrauma 1 month later. However, further study investigating the safety of performing PDT in patients with preexisting barotrauma is still underway.

In summary, PDT can worsen preexisting barotrauma. Thus, it is suggested to postpone the procedure until resolution or at least stabilization of barotrauma. Once the decision is made to perform PDT, it should be performed by an experienced operator, using the most time-saving procedure. In addition, ventilating patients with pressure control mode, shortening the bronchoscopy time, and administering enough postoperative sedation and pain control are important factors in preventing further deterioration of barotrauma.

REFERENCES

1. Ciaglia P, Firsching R, Syniec C. Elective percutaneous dilatational tracheostomy. A new simple bedside procedure; preliminary report. *Chest* 1985;87:715-9.
2. Freeman BD, Isabella K, Cobb JP, et al. A prospective, randomized study comparing percutaneous with surgical

- tracheostomy in critically ill patients. *Crit Care Med* 2001;29:926–30.
3. Friedman Y, Fildes J, Mizock B, et al. Comparison of percutaneous and surgical tracheostomies. *Chest* 1996;110:480–5.
 4. Heikkinen M, Aarnio P, Hannukainen J. Percutaneous dilational tracheostomy or conventional surgical tracheostomy? *Crit Care Med* 2000;28:1399–402.
 5. Ernst A, Critchlow J. Percutaneous tracheostomy—special considerations. *Clin Chest Med* 2003;24:409–12.
 6. Mansharamani NG, Koziel H, Garland R, et al. Safety of bedside percutaneous dilatational tracheostomy in obese patients in the ICU. *Chest* 2000;117:1426–9.
 7. Beiderlinden M, Groeben H, Peters J. Safety of percutaneous dilational tracheostomy in patients ventilated with high positive end-expiratory pressure (PEEP). *Intensive Care Med* 2003;29:944–8.
 8. Kluge S, Meyer A, Kuhnelt P, et al. Percutaneous tracheostomy is safe in patients with severe thrombocytopenia. *Chest* 2004;126:547–51.
 9. Meyer M, Critchlow J, Mansharamani N, et al. Repeat bedside percutaneous dilational tracheostomy is a safe procedure. *Crit Care Med* 2002;30:986–8.
 10. Byhahn C, Lischke V, Halbig S, et al. Ciaglia blue rhino: a modified technique for percutaneous dilatation tracheostomy. Technique and early clinical results. *Anaesthesist* 2000;49:202–6.
 11. Fikkers BG, van Veen JA, Kooloos JG, et al. Emphysema and pneumothorax after percutaneous tracheostomy: case reports and an anatomic study. *Chest* 2004;125:1805–14.
 12. Massick DD, Powell DM, Price PD, et al. Quantification of the learning curve for percutaneous dilatational tracheotomy. *Laryngoscope* 2000;110:222–8.

已有氣壓傷害之病患接受經皮氣切手術 之安全性

許超群 蔡忠榮 鄭孟軒 鍾欽文

黃明賢 黃吉志

高雄醫學大學附設醫院 內科部 胸腔內科

自從 Ciaglia 等人於 1985 年引進經皮氣切手術以來，它已成為許多加護病房為病患建立長期氣道之標準氣切手術。然而，在已有氣壓傷害之病患進行經皮氣切手術是否安全仍是未知，且未有相關之文獻報告。我們所報告的案例是一位三十五歲的愛滋病患，他因肺炎併發急性呼吸窘迫症候群而轉入我們內科加護病房。病患後來因使用呼吸器而併發皮下氣腫和縱膈氣胸等氣壓傷害。待其氣壓傷害穩定後，我們為其施行 **Ciaglia Blue Rhino** 之經皮氣切手術。然而，其原有皮下氣腫和縱膈氣胸卻在經皮氣切術後快速且嚴重地惡化。我們認為因氣切手術過長，導致原本就較為脆弱的肺部組織長時間曝露在高氣道壓力下是其氣壓傷害快速惡化的主要機轉。病患最終成功脫離呼吸器並已出院。為避免未來發生同樣的併發症，我們提出一些應嚴格遵守之安全性原則。在此原則下，我們於一個月後安全地為另一位已有氣壓傷害之病患施行經皮氣切手術。

關鍵詞：氣壓傷害，經皮氣切術，縱膈氣胸，皮下氣腫

(高雄醫誌 2006;22:570-4)

收文日期：95 年 2 月 7 日

接受刊載：95 年 6 月 9 日

通訊作者：黃吉志醫師

高雄醫學大學附設醫院內科部胸腔內科

高雄市807三民區自由一路100號