

TREATMENT FOR FROZEN SHOULDER COMBINED WITH CALCIFIC TENDINITIS OF THE SUPRASPINATUS

Shen-Kai Chen,^{1,2} Pei-Hsi Chou,^{1,2} Yi-Jing Lue,^{3,4} and Yen-Mou Lu¹

Departments of ¹Orthopedics and ⁴Rehabilitation, Kaohsiung Medical University Hospital,
²Faculty of Sports Medicine, College of Medicine, Kaohsiung Medical University, and
³Faculty of Physical Therapy, College of Health Sciences, Kaohsiung Medical University,
Kaohsiung, Taiwan.

Calcific tendinitis of the shoulder is a process that involves calcium deposition in the rotator cuff tendons. It is usually a self-limiting process and is often chronic in nature. However, it can lead to acute pain resulting in frozen shoulder syndrome. We report 32 cases in which frozen shoulder was associated with calcific tendinitis of the supraspinatus. The aim of this study was to use arthroscopic brisement of the glenohumeral joint and make multiple punctures in the calcific spot to treat the frozen shoulder associated with calcific tendinitis of the supraspinatus. In our study, 30 patients had satisfactory results after a 2-year follow-up. Five patients experienced some postoperative calcium shadows, but there was also greater improvement in the range of motion and pain relief in this study compared with other reports in the literature of frozen shoulder cases.

Key Words: calcific tendinitis, frozen shoulder
(*Kaohsiung J Med Sci* 2008;24:78–84)

Although the etiology of frozen shoulder remains elusive, understanding of its pathophysiology has improved. Most researchers agree that immobility is the most important factor in the etiology of frozen shoulder [1–4]. Harryman [5] and Neviasser [6] have reported series of patients with primary idiopathic frozen shoulder and no predisposing factors. However, most cases are initiated by and secondary to other diseases. The precipitating factors may be within the shoulder (calcific tendinitis, rotator cuff inflammation, bicipital tendinitis, fractures) or from extra-articular abnormalities (angina pectoris, cervical spondylosis, hyperthyroidism or diabetes mellitus). The apparent

confusion results from the difficulty in distinguishing primary changes from secondary changes, and in deciding if the capsule abnormalities have resulted from inflammation of the surrounding structures or vice versa. The goal when treating frozen shoulders is to restore motion and thereby improve shoulder function and pain relief. A number of therapeutic interventions have been reported with mixed results, including analgesic medication, oral steroids, physical therapy [7], nerve block, intra-articular injections, manipulation [8], distention arthrography [9,10], and arthroscopic [11–13] or open release [14]. If a frozen shoulder is induced by an underlying lesion such as calcific tendinitis of the supraspinatus, it is also necessary to address the pathologic changes [15]. The aim of this study was to report the outcome of using arthroscopic brisement of the glenohumeral joint and making multiple punctures in the calcific spot to treat frozen shoulder associated with calcific tendinitis of the supraspinatus.



ELSEVIER

Received: Aug 22, 2007 Accepted: Oct 29, 2007
Address correspondence and reprint requests to:
Dr Yen-Mou Lu, Department of Orthopedics,
Kaohsiung Medical University Hospital, 100
Tzyou 1st Road, Kaohsiung 807, Taiwan.
E-mail: yemolu@kmu.edu.tw

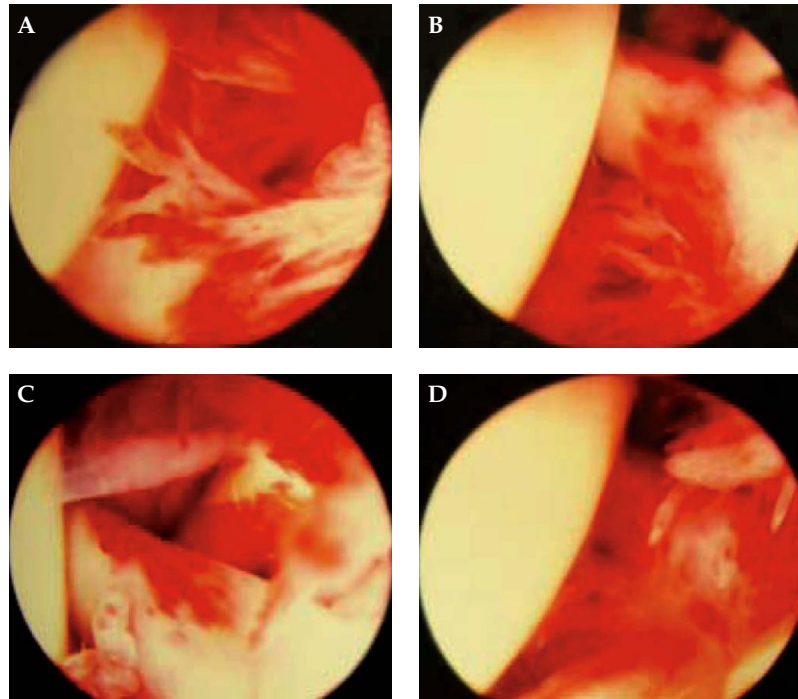


Figure 1. The arthroscopic appearance of the joint is dependent on the stage of adhesive capsulitis.

METHODS

From June 2001 to January 2005, 32 cases of frozen shoulder associated with calcific tendinitis of the supraspinatus were analyzed at Kaohsiung Medical University Hospital. A diagnosis of frozen shoulder was made on the basis of history, physical examination, X-ray and, occasionally, magnetic resonance imaging. The patients' ages ranged from 32 to 79 years and the mean was 58 years (8 males, 24 females). The duration of symptoms ranged from 2 to 13 months, and was 5 months on average.

Pure glenohumeral motion was measured while limiting scapulothoracic motion. Active and passive forward flexion, abduction, internal rotation (measured in the coronal plane at 90 degrees of abduction) and external rotation in neutral abduction were measured and recorded with the patient in the supine position. Routine radiographic evaluation included anteroposterior views of internal and external rotation, and axillary views for confirming calcific tendonitis localized in the supraspinatus insertion region.

After general anesthesia, it is essential to document the degree of glenohumeral joint motion before initiating the surgical procedure, since it may be difficult to insert the arthroscope into a stiff joint because

of capsular contraction, allowing distension by water and causing the syringe to rebound. The arthroscopic appearance of the joint is dependent on the stage of adhesive capsulitis (Figure 1). A thorough synovectomy can be achieved either by shaver or vaporization after distending the glenohumeral joint. A sheet of capsular scar and synovial adhesions, which may obscure the rotator cuff interval region and the biceps tendon, can be debrided carefully. After debriding the intra-articular synovial adhesions, the anterior capsule becomes clear. Figure 2 shows the anterior capsule release at this point. The arthroscopic instruments were removed and a gentle manipulation was performed in the next step. The arm was first elevated in the scapular plane. This maneuver was invariably associated with audible popping of the contracted capsule. The arm was then externally rotated at varying degrees of abduction. Finally, the shoulder was internally rotated to varying degrees of abduction, and the cycle was repeated. Manipulation was not overly forceful, but was performed with gradual pressure and was stopped if unyielding resistance was met. Then, the scope was shifted to the subacromial space to shave and debride the inside adhesive scarred tissue. After visualization was achieved, multiple punctures were easily made

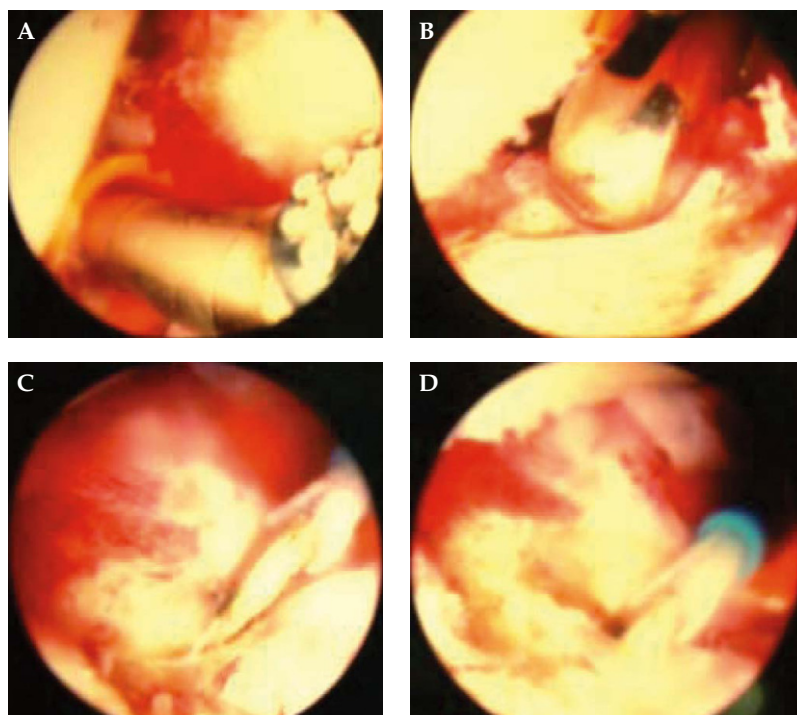


Figure 2. After debridement of the intra-articular synovial adhesion, the anterior capsule became clearer than before. At this point, anterior capsule release was performed.

under arthroscopic visualization (Figure 3) using a no. 18 needle to reach the calcium spots localized at the greater tuberosity. Some of the calcium materials could be washed out, but others could not (Figure 4).

After the arthroscopic procedures and multiple punctures of the calcium spots, passive and active exercise of the shoulder was allowed immediately if the patient could tolerate it. Ice packing over the puncture region was applied. An intensive rehabilitation program was encouraged at the hospital rehabilitation facility. Routine rechecks of X-rays at 3 weeks, 3 months and 1 year postoperatively were performed to evaluate the calcific tendonitis status. All of the patients were evaluated postoperatively, from 13 months to 3 years, and received an American Shoulder and Elbow Surgeons Shoulder Score [16], a subjective scoring tool designed to assess pain, patient satisfaction and function. The maximum overall score is 100 points, of which 30 points are awarded for pain, 10 points for patient satisfaction, and 60 points for function.

Statistical analysis

Paired *t* tests were used to assess changes between before and after treatment. The α level was set at 0.05. Statistical analyses were performed using SPSS version 12.0 (SPSS Inc., Chicago, IL, USA).

RESULTS

The mean duration of follow-up was 19 months (range, 13 months to 3 years). No early or late complications were noted in this group. A significant improvement was seen in the mean shoulder score. The mean shoulder score at the time of follow-up was 86.4 ± 10.5 , compared with the preoperative score of 40.8 ± 12.6 ($p < 0.0001$). The normal range of shoulder movement varied with the individual, particularly in external rotation. Although movement in each plane was recorded separately, we found that the most useful indices of progress were elevation and external rotation. The former is most useful for function, and the latter is most resistant to management. At the latest follow-up, the average gain in elevation for all patients was 42.5 degrees. The average gain in external rotation and internal rotation was 35.8 and 30.6 degrees. The absolute degree of motion does not carry clinical significance as a reference of progress, and where possible, we preferred to express values as a percentage of the values on the unaffected side. In terms of shoulder elevation, it was found that 30 out of 32 shoulders recovered completely by 3 months.

Reduced pain might suggest resolution of the disease process, and persistence of severe pain may be

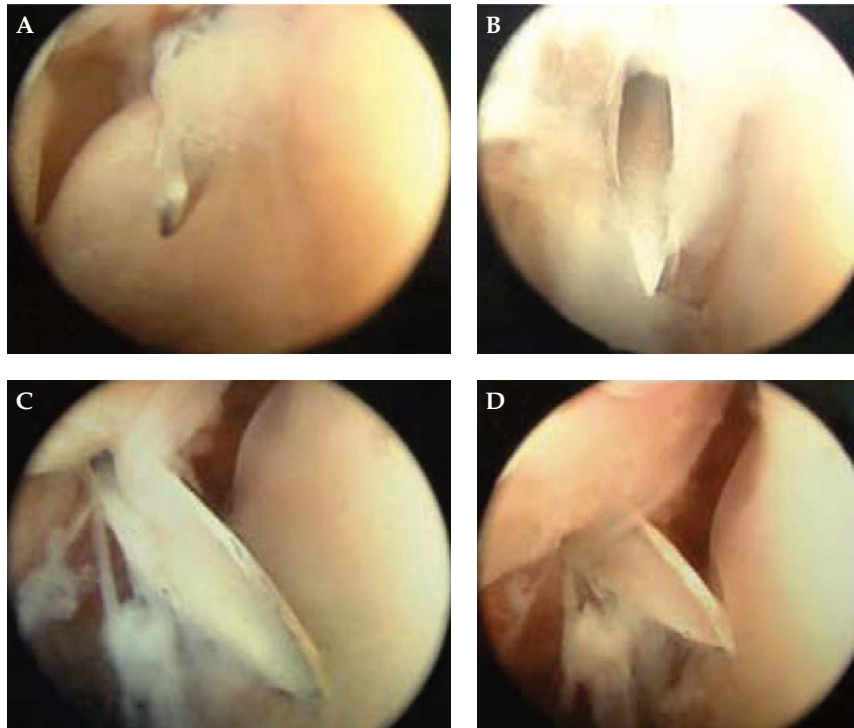


Figure 3. Multiple punctures were easily made under arthroscopic visualization.

equated with continuing disease activity. Therefore, the outcome of treatment might be expected to vary with pain intensity at presentation. Half of the patients had pain relief within 1 month, whether in motion or not. Three months later, most of the patients felt pain-free in any direction of shoulder movement, with the exception of two shoulders.

We attempted to assess the calcium status during the follow-up period. Ten of the patients had no calcium shadows at the 3-week follow-up (Figures 5 and 6). Five patients did have some postoperative calcium shadows, even after 1 year.

DISCUSSION

Frozen shoulder is still a poorly understood disease process and the cause remains unknown. Patients with adhesive capsulitis experience pain and subsequent restriction of shoulder motion. However, in secondary series, most cases are initiated by secondary disease. The purpose of this study was to analyze the outcome of arthroscopic brisement of the glenohumeral joint and multiple punctures and removal of the calcium spot on the rotator cuff, and to document the postoperative evaluation.

Amorphous calcium deposits occur in many soft tissues, causing pain and dysfunction. The most common site of deposition is the rotator cuff of the shoulder. Calcification usually occurs in the supraspinatus portion of the cuff as a healing response to injury or overuse [17]. The physical characteristics of the calcium deposit will greatly influence the type of pain experienced by the patient. If the calcium is in liquid form, an acute process will ensue. If the deposit is dry and hard, a chronic form is produced, characterized by less intense pain, but with a limited range of shoulder motion, and secondary frozen shoulder will develop [18].

The precise composition of calcium deposits in calcifying tendinitis is still unknown. However, analysis of such deposits can help to elucidate the disease's pathogenesis. Twenty-five calcium deposits from various phases of the disease were analyzed by several methods [19]. The macroscopic appearance of specimens obtained during the acute phase of calcifying tendinitis resembled a milky emulsion. In contrast, during the chronic phase, these resembled a granular conglomerate. X-ray diffraction showed a poorly crystallized hydroxyapatite lattice (resembling that in bone) in both phases. Infrared spectroscopy revealed variable H_2O , CO_3 , and PO_4 contents in all samples,

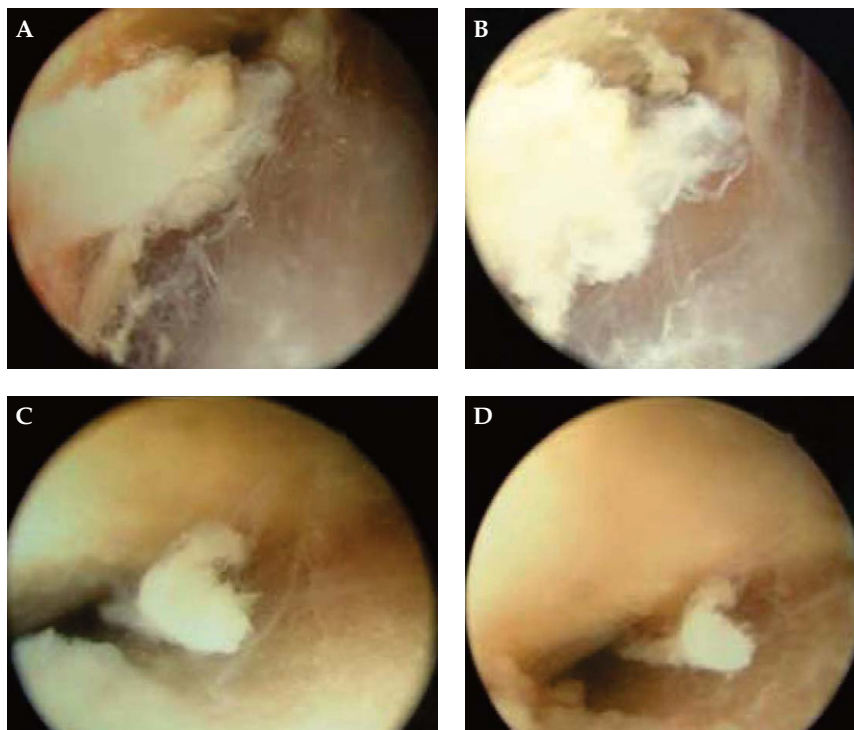


Figure 4. Some of the calcium materials were washed out, but others could not be.

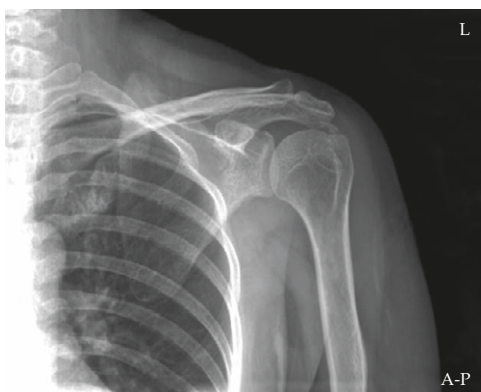

Figure 5. Left shoulder film shows a calcific spot over the supraspinatus tendon in case 1.

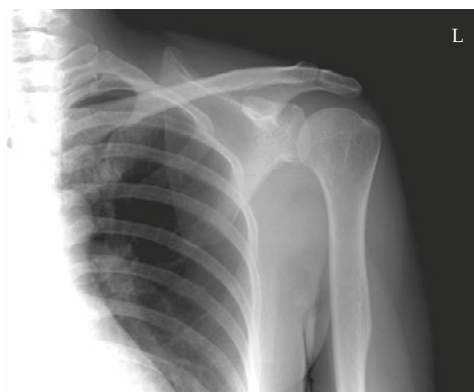

Figure 6. X-ray shows no calcium shadows at the 3-week follow-up of case 1.

but no significant differences in these proportions were seen in the two phases of the disease [20]. Additionally, organic molecules were seen in all samples.

Several studies have shown that the use of arthroscopy and manipulation under general anesthesia to treat frozen shoulder patients produces good results with a low complication rate. In our study, we found that 90% of patients had satisfactory results after arthroscopic brisement. Even though many patients did have some postoperative ache, this pain subsided in all patients within a further 2-week period. Hence,

the pain resolved within 12 weeks of surgery and the total range of motion returned as well.

Those patients with postoperative elimination or reduction of the calcium deposits had significantly better outcomes than those who had little radiographic changes [21]. Acromioplasty should not be performed without radiographic signs of impingement. If a resulting large rotator cuff defect is found after removal of the calcium deposit, it may be worthwhile to close the defect arthroscopically with sutures to prevent cuff tear progression and to promote healing [22]. The aim of

arthroscopic treatment in frozen shoulder combined with calcific tendinitis of the supraspinatus is to remove the calcium deposit in addition to brisement of the glenohumeral joint [23]. Based on radiographs at 1-year follow-up, 84% (27 of 32) of the calcifications had disappeared, including 31% (10 of 32) that had disappeared by 3 weeks and 53% (17 of 32) that had disappeared by 3 months postoperatively; 15.6% (5 of 32) had some calcium shadows present at the 1-year follow-up. In our series, only two of five residual calcific tendonitis cases had recurrent frozen shoulders during the 1 to 2 years after the operation compared with the other 27 cases who had no recurrence.

Systematic exploration of the glenohumeral joint is not relevant in the arthroscopic treatment of calcified tendonitis, and has a negative effect. Considering these results and those previously published in the literature [24], we recommend using an isolated bursal approach for the removal of arthroscopic calcifying tendonitis. Multiple needle punctures of calcium deposits were carried out by moving the point of the needle into and out of the deposit under arthroscopic visualization. This maneuver is used to break up the localized deposit, lessen its tension, and to increase vascularity. If the calcium was in liquid form, it may be aspirated by a syringe.

Frozen shoulder combined with calcific tendinitis of the supraspinatus can be treated by arthroscopic brisement of the glenohumeral joint and by making multiple punctures in the calcium spot, from the bursal side, under arthroscopic visualization. To prevent recurrence, the calcium spots must be cleaned totally, and a thorough exercise program adhered to. In conclusion, the outcome of treatment is related to calcium status.

REFERENCES

- Gartner J, Heyer A. Calcific tendinitis of the shoulder. *Orthopade* 1995;3:284-302.
- Anton HA. Frozen shoulder. *Can Fam Physician* 1993; 39:1773-8.
- Pearsall AW, Speer KP. Frozen shoulder syndrome: diagnostic and treatment strategies in the primary care setting. *Med Sci Sports Exerc* 1998;30(4 Suppl):S33-9.
- Cutts S, Clarke D. The patient with frozen shoulder. *Practitioner* 2002;246:730,734-6,738-9.
- Harryman DT 2nd. Shoulders: frozen and stiff. *Instr Course Lect* 1993;42:247-57.
- Neviaser TJ. Adhesive capsulitis. *Orthop Clin North Am* 1987;18:439-43.
- Mao CY, Jaw WC, Cheng HC, et al. Frozen shoulder: correlation between the response to physical therapy and follow-up shoulder arthrography. *Arch Phys Med Rehabil* 1997;78:857-9.
- Xu HZ, Yu B, Zhang QG, et al. Treatment of 48 cases of frozen shoulder with manual therapy under brachial plexus anesthesia through a retained tube. *Di Yi Jun Yi Da Xue Xue Bao* 2003;23:87-8.
- Rizk TE, Gavant ML, Pinals RS. Treatment of adhesive capsulitis (frozen shoulder) with arthrographic capsular distension and rupture. *Arch Phys Med Rehabil* 1994; 75:803-7.
- Wybier M, Parlier-Cuau C, Baque MC, et al. Distension arthrography in frozen shoulder syndrome. *Semin Musculoskelet Radiol* 1997;1:251-6.
- Zanotti RM, Kuhn JE. Arthroscopic capsular release for the stiff shoulder—description of technique and anatomic considerations. *Am J Sports Med* 1997;25: 294-8.
- Kilian O, Kriegsmann J. The frozen shoulder arthroscopy, histological findings and transmission electron microscopy imaging. *Chirurg* 2001;72:1303-8.
- Chen, SK, Chien SH, Fu YC, et al. Idiopathic frozen shoulder treated by arthroscopic brisement. *Kaohsiung J Med Sci* 2002;18:289-94.
- Uhthoff HK. Open surgical release for frozen shoulder—author reply. *J Shoulder Elbow Surg* 2002;11:200.
- Ark JW, Flock TJ. Arthroscopic treatment of calcific tendinitis of the shoulder. *Arthroscopy* 1992;8:183-8.
- Richards RR, An KN, Bigliani LU, et al. A standardized method for the assessment of shoulder function. *J Shoulder Elbow Surg* 1994;3:347-52.
- Speed CA, Hazleman BL. Calcific tendinitis of the shoulder. *N Engl J Med* 1999;340:1582-4.
- Noel E. Treatment of calcific tendinitis and adhesive capsulitis of the shoulder. *Rev Rhum Engl Ed* 1997; 64:619-28.
- Farin PU. Consistency of rotator-cuff calcifications—observations on plain radiography, sonography, computed tomography, and at needle treatment. *Invest Radiol* 1996;31:300-4.
- Gartner J, Simons B. Analysis of calcific deposits in calcifying tendinitis. *Clin Orthop Relat Res* 1990; 254:111-20.
- Sirveaux F, Gosselin O. Postoperative results after arthroscopic treatment of rotator cuff calcifying tendonitis, with or without associated glenohumeral exploration. *Rev Chir Orthop Reparatrice Appar Mot* 2005;91:295-9.
- Hurt G, Baker CL Jr. Calcific tendinitis of the shoulder. *Orthop Clin North Am* 2003;34:567-75.
- Mole D, Kempf JF, Gleyze P, et al. Results of endoscopic treatment of non-broken tendinopathies of the rotator cuff. 2. Calcifications of the rotator cuff. *Rev Chir Orthop Reparatrice Appar Mot* 1993;79:532-41.
- Jerosch J, Strauss JM, Schmiel S, et al. Arthroscopic treatment of calcific tendinitis of the shoulder. *J Shoulder Elbow Surg* 1998;7:30-7.

冷凍肩合併鈣化性肌腱炎的治療

陳勝凱^{1,2} 周伯禧^{1,2} 呂怡靜^{3,4} 呂衍謀¹

高雄醫學大學附設醫院 ¹骨科 ⁴復健科

²高雄醫學大學 醫學院 運動醫學系

³高雄醫學大學 健康科學院 物理治療學系

鈣化性肌腱炎最常發生的位置之一就是肩部的旋轉袖口肌腱，雖然鈣的沈澱在此處常的是慢性顯現並不一定會有症狀產生，然而在急性發作期會引發冷凍肩的病症。本篇收集 32 個冷凍肩合併鈣化性肌腱炎的病例，利用關節鏡裂斷術 (arthroscopic brisement) 合併在關節鏡視野下施行多次針刺 (multiple punctures) 在肌腱鈣化處，來治療此合併症。經過平均兩年的追蹤，在本系列有 30 個病例得到滿意的結果。在追蹤期間仍有 5 例有尚餘存的鈣沈澱影像，但這些病例和其他文獻上有關治療冷凍肩的報告比較，仍有較好的關節活動度和疼痛的緩解。

關鍵詞：鈣化性肌腱炎，冷凍肩

(高雄醫誌 2008;24:78-84)

收文日期：96 年 8 月 22 日

接受刊載：96 年 10 月 29 日

通訊作者：呂衍謀醫師

高雄醫學大學附設醫院骨科

高雄市807三民區自由一路100號