

# ELEVATION OF INTRAOCULAR PRESSURE AFTER INTRAVITREAL INJECTION OF TRIAMCINOLONE ACETONIDE IN TAIWANESE PATIENTS

Yo-Chen Chang<sup>1</sup> and Wen-Chuan Wu<sup>2,3</sup>

<sup>1</sup>Department of Ophthalmology, Kaohsiung Municipal Hsiao-Kang Hospital, Kaohsiung Medical University, <sup>2</sup>Department of Ophthalmology, Kaohsiung Medical University Hospital, and <sup>3</sup>Department of Ophthalmology, Faculty of Medicine, College of Medicine, Kaohsiung Medical University, Kaohsiung, Taiwan.

The purpose of this study was to investigate the incidence and timing of elevation in intraocular pressure (IOP) after intravitreal injection of triamcinolone acetonide (IVTA). This was a retrospective observational case series that included 52 eyes from 52 patients. All patients received intravitreal injection with 4 mg of triamcinolone acetonide. Significant IOP elevation was defined as pressure greater than 21 mmHg. There were 26 males and 26 females included in this study. The mean age was 59.4 years. The mean IOP at baseline and postoperative mean highest IOP were 14.6 mmHg and 21.5 mmHg, respectively. There were 19 (36.5%) patients who experienced significant IOP elevation at a mean of 26.0 days after IVTA. IOP was well-controlled by topical antiglaucoma medication in 17 of these 19 patients. IOP elevation after intravitreal injection with 4 mg of triamcinolone acetonide is not a rare finding. This phenomenon usually starts approximately 1 month after IVTA. Patients considering this treatment should be fully informed of this known adverse effect.

**Key Words:** corticosteroid-induced glaucoma, intraocular pressure, intravitreal injection, triamcinolone acetonide

(*Kaohsiung J Med Sci* 2008;24:72-7)

In 1995, Penfold et al reported a pilot study of intravitreal injection of 4 mg of triamcinolone acetonide (IVTA) to treat exudative age-related macular degeneration with encouraging results [1]. Thereafter, intravitreal injection of triamcinolone acetonide became a useful therapeutic option for many conditions, including ocular inflammatory diseases [2], retinal veno-occlusive disease [3], diabetic macular edema [4] and ocular choroidal neovascularization [5]. One of the ocular side effects of corticosteroids is the

elevation of intraocular pressure (IOP) [6,7]. As the expansion of indications and use of IVTA increases, the incidence of corticosteroid-induced glaucoma associated with IVTA will become more commonly encountered by ophthalmologists. The purpose of this study was to investigate the incidence of significant IOP elevation, the magnitude of the IOP rise after IVTA and the interval between IVTA and the subsequent increase in IOP in Taiwanese patients.

## METHODS

### *Patient selection*

A retrospective chart review was performed between September 2004 and December 2005. Initial preoperative evaluation included visual acuity, slit-lamp



ELSEVIER

Received: Jun 26, 2007 Accepted: Sep 12, 2007  
Address correspondence and reprint requests to:  
Dr Wen-Chuan Wu, Department of Ophthalmology,  
Kaohsiung Medical University, 100 Tzyou  
1<sup>st</sup> Road, Kaohsiung 807, Taiwan.  
E-mail: wcwu.oph@gmail.com

biomicroscopy, indirect ophthalmoscopy, IOP measurement by Goldmann applanation tonometry and glaucoma survey by a glaucoma specialist in our department. Eyes with any type of glaucoma (open-angle glaucoma, angle-closure glaucoma, secondary glaucoma associated with its original eye disease) at baseline were excluded from this study. All patients gave written informed consent. For those patients who received IVTA in both eyes, only the first eye to receive an injection was included in this study.

### **Surgical procedure**

Under topical anesthesia, IVTA was performed under sterile conditions in the operation room with an operation microscope. Povidone-iodine (Saint-iodine®; Patron, Gangshan, Taiwan) was applied before IVTA. Then, the patient was completely draped. We used a lid speculum to open the eye. Paracentesis into the anterior chamber was performed and some aqueous fluid was aspirated using a 26-gauge needle with a 1.0-mL tuberculin syringe to reduce the volume of the eye. We used triamcinolone acetonide 40 mg/mL suspension (Kenalog; Bristol-Myers Squibb, New Brunswick, NJ, USA) directly from the vial without attempting to isolate the supernatant from the crystals. The injection of crystalline triamcinolone acetonide (4 mg in 0.1 mL) into the vitreous cavity was performed using a sharp 27-gauge needle through the inferior temporal pars plana [2,3,5,8]. A prophylactic antibiotic eye drop was then applied.

### **Postoperative follow-up**

Thereafter, patients were examined on the first day, 1 week, 2 weeks and 4 weeks after the injection, followed by reevaluation at monthly intervals. If postoperative IOP exceeded 21 mmHg, which was defined as significant IOP elevation, topical antiglaucoma therapy was prescribed. If IOP continued to be elevated despite maximal medical treatment, filtering surgery was indicated.

### **Statistical analysis**

Statistical analysis was performed using JMP statistical software version 5.1.2 (SAS Institute Inc., Cary, NC, USA). The IOP at baseline and postoperative maximal IOP were compared using a paired *t* test. Analyses of descriptive data (postoperatively significant IOP elevation *vs.* gender, ocular diagnosis for IVTA, diabetes mellitus and hypertension) were performed using

Pearson's  $\chi^2$  test. The level of significance was 0.05 (two-sided) in all statistical tests.

## **RESULTS**

### **Demographic data**

This study included 52 eyes from 52 patients. There were 26 males and 26 females included in this study. The mean age was  $59.4 \pm 11.3$  years. Regarding systemic disease, 25 patients had diabetes mellitus and 26 had essential hypertension. Preoperative ocular diagnosis included diabetic cystoid macular edema (30.8%), central retinal vein occlusion (23.1%), branch retinal vein occlusion (23.1%) and other ocular diagnoses that included neovascular age-related macular degeneration and uveitis-associated macular edema. The mean follow-up time was  $42.1 \pm 6.5$  weeks. Detailed demographic data are shown in Table 1.

### **Postoperative follow-up**

The mean IOP at baseline was  $14.6 \pm 2.9$  mmHg (range, 9–20 mmHg). There was a significant increase ( $p < 0.001$ ) in the mean maximal IOP of  $21.5 \pm 8.1$  mmHg (range, 11–49 mmHg) postoperatively. The mean maximal pressure increase was  $6.9 \pm 7.9$  mmHg (range, –2–36 mmHg). During the follow-up period, there were 19 eyes (36.5%) that experienced a significant IOP elevation (i.e. IOP > 21 mmHg after IVTA). Among these 19 patients, the timing of significant IOP

**Table 1.** Demographic data of the 52 patients (52 eyes)\*

Gender	
Male	26 (50.0)
Female	26 (50.0)
Age (yr)	$59.4 \pm 11.3$ (18–78)
Medical history	
Diabetes mellitus	25 (48.1)
Hypertension	26 (50.0)
Reason for treatment	
Diabetic macular edema	16 (30.7)
Central retinal vein occlusion	12 (23.1)
Branch retinal vein occlusion	12 (23.1)
Others	12 (23.1)
Follow-up period (wk)	$42.1 \pm 6.5$ (32–60)
Number of follow-up visits	$13.0 \pm 1.5$ (11–16)

\*Data presented as mean (%) or mean  $\pm$  standard deviation (range).

elevation occurred at a mean of  $26.0 \pm 9.8$  days (range, 14–60 days) after IVTA. By  $\chi^2$  analysis, significant IOP elevation was not significantly associated with gender, ocular diagnosis for IVTA, diabetes mellitus or hypertension. Detailed data on IOPs at baseline and during the postoperative period are shown in Table 2.

Figure 1 shows the timing of significant IOP elevation during the follow-up period. The rise in IOP occurred most frequently between 2 weeks and 4 weeks after injection. After 60 days postoperatively, no new cases of glaucoma were observed. Figure 2 demonstrates the IOP measurements of eyes with  $IOP > 21$  mmHg and those with  $IOP \leq 21$  mmHg during

the follow-up period. The highest IOP usually occurred 1 month after injection, in both groups.

Among the 19 patients who experienced significant IOP elevation, 17 (89.4%) could be well controlled with a mean of  $1.7 \pm 1.1$  (range, 1–4) antiglaucoma medications (e.g.  $\beta$ -blockers,  $\alpha_2$ -agonists). Despite maximal medical therapy, the IOPs of the other two patients remained high and these patients required filtering surgery. After operation, the IOPs of both eyes lowered to within the normal range without additional antiglaucoma medication.

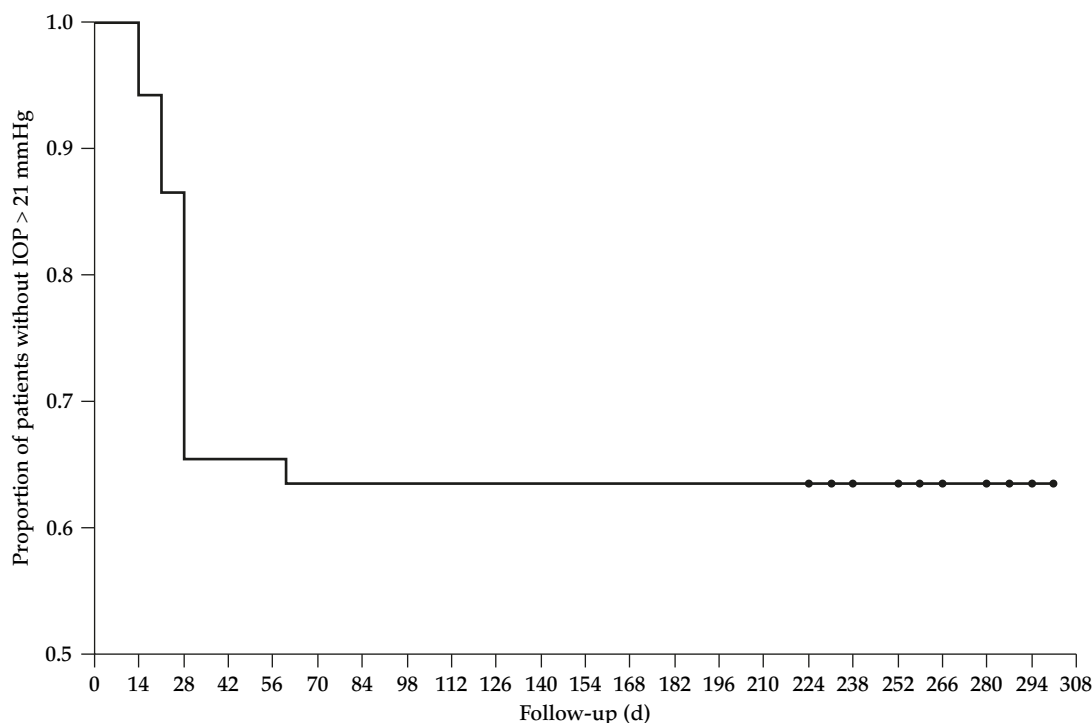
## DISCUSSION

It has been known for many years that increased IOP can occur as a consequence of oral, intravenous, inhaled, topical, pericocular or intravitreal corticosteroid therapy [9–13]. If it is not recognized or well-treated, subsequent glaucomatous optic neuropathy might develop. The aim of this study was to investigate the incidence and timing of significant IOP elevation after intravitreal injection of 4 mg triamcinolone acetonide. In our study, none of the patients had a diagnosis of glaucoma before the injection. The overall

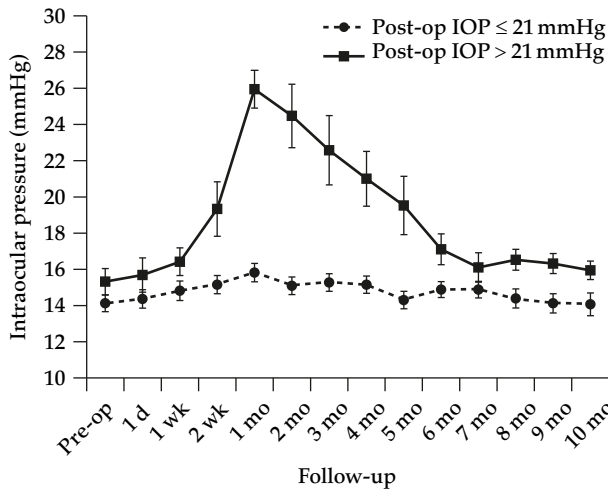
**Table 2.** Intraocular pressure (IOP) at baseline and throughout the follow-up period\*

IOP at baseline	$14.6 \pm 2.9$ (9–20) mmHg
Postoperative IOP	
Maximal postoperative IOP	$21.5 \pm 8.1$ (11–49) mmHg
Maximal IOP increase	$6.9 \pm 7.9$ (–2–36) mmHg
IOP > 21 mmHg	19 eyes (36.5%)
Days to IOP > 21 mmHg	$26.0 \pm 9.8$ (14–60)

\*Data presented as mean  $\pm$  standard deviation (range).



**Figure 1.** Survival plot shows the proportion of eyes with intraocular pressure (IOP) > 21 mmHg with time after the injection. Eyes experiencing IOP > 21 mmHg usually occurred between 14 and 28 days postoperatively.



**Figure 2.** Intraocular pressure (IOP) measurements at baseline and after injection in eyes with postoperative IOP >21 mmHg versus eyes with postoperative IOP ≤21 mmHg. The highest IOP was usually measured 1 month after injection in both groups.

incidence of significant IOP elevation after IVTA was 36.5% occurring at a mean of approximately 4 weeks. Beer et al reported a mean elimination half-life of 18.6 days in five nonvitrectomized patients after intravitreal injection of 4 mg triamcinolone acetonide [14]. Our result of significant IOP elevation at a mean of 26.0 days indicates that the adverse effect of triamcinolone acetonide may extend more than one half-life after the injection. The slope of a survival curve stabilized 8 weeks after IVTA, suggesting that patients had low risk for significant IOP elevation 2 months after IVTA. In patients who did not experience significant IOP elevation, most had maximal IOP 4 weeks after IVTA. This suggests that patients receiving IVTA should at least have regular follow-ups in the first 1–2 months after the injection.

In a study by Jonas et al, 41.2% of eyes experienced a pressure greater than 21 mmHg with the rise occurring from 1 week to 2 months after the injection [15]. This timing of IOP rise was similar to our results. However, the incidence was higher than our results. The possible explanation for the higher incidence of significant IOP elevation might be the higher dosage of triamcinolone acetonide (20 mg *vs.* 4 mg) used in their study. The mechanism of corticosteroid-induced ocular hypertension is increased aqueous outflow resistance [16]. Corticosteroids can induce physical and mechanical changes in the

microstructure of the trabecular meshwork causing an increase in the deposition of substances in the trabecular meshwork, thereby decreasing aqueous outflow [17].

There is an increasing concern about the preservative vehicle used to administer triamcinolone acetonide. Benzyl alcohol has been implicated in cases of sterile endophthalmitis after intravitreal injection [18,19]. Mauricio et al reported that noninfectious endophthalmitis was observed significantly more often in eyes treated with triamcinolone acetonide containing preservatives than in those treated with preservative-free triamcinolone acetonide, but both groups had similar rates of postoperative ocular hypertension [20]. Different techniques to reduce the amount of benzyl alcohol in commercially prepared triamcinolone acetonide, including sedimentation, centrifugation and filter techniques, have been reported in an attempt to reduce toxicity [21–23]. All of these different techniques employed effectively reduced the concentration of benzyl alcohol [20]. However, in most studies, a dose of 4 mg with preservatives was widely used [24].

Most patients with significant IOP elevations after IVTA can be well managed with topical antiglaucoma medication. According to our results, 89.4% of patients who experienced significant IOP elevation were successfully controlled by topical eye drops. There were only two patients who received filtering surgery to control IOP. However, traditional filtering surgery is not the only option. Agrawal et al reported pars plana vitrectomy with removal of intraocular triamcinolone acetonide particles in the vitreous cavity to treat eyes with intractable IOP elevation [25].

In conclusion, according to our results, intravitreal injection of 4 mg of triamcinolone acetonide can lead to significant IOP elevation in approximately one-third of patients, occurring at a mean of 4 weeks after injection. Patients who are treated with this procedure should be fully informed about this common side effect, and regular follow-up for IOP in the first 2 months is usually necessary.

## ACKNOWLEDGMENTS

The authors would like to thank the Statistical Analysis Laboratory, Department of Clinical Research, Kaohsiung Medical University Hospital for their help.

## REFERENCES

1. Penfold PL, Gyovy JF, Hunyor AB, et al. Exudative macular degeneration and intravitreal triamcinolone—a pilot study. *Aust NZ J Ophthalmol* 1995;23:293–8.
2. Young S, Larkin G, Branley M, et al. Safety and efficacy of intravitreal triamcinolone for cystoid macular edema in uveitis. *Clin Exp Ophthalmol* 2001;29:2–6.
3. Greenberg PB, Martidis A, Roger AH, et al. Intravitreal triamcinolone acetonide for macular edema due to central retinal vein occlusion. *Br J Ophthalmol* 2002;86:247–8.
4. Jonas JB, Sofker A. Intraocular injection of crystalline cortisone as adjunctive treatment of diabetic macular edema. *Am J Ophthalmol* 2001;132:425–7.
5. Danis RP, Ciulla TA, Pratt LM, et al. Intravitreal triamcinolone acetonide in exudative age-related macular degeneration. *Retina* 2000;20:244–50.
6. McLean JM. Use of ACTH and cortisone. *Trans Am Ophthalmol Soc* 1950;48:293–6.
7. Francois J. Cortisone et tension oculaire. *Ann D'Oculist* 1984;187:805.
8. Cheng KC, Wu WC. Intravitreal triamcinolone acetonide for patients with macular edema due to branch retinal vein occlusion. *Kaohsiung J Med Sci* 2006;22:321–30.
9. Bernstein HN, Mill DW, Becker B. Steroid-induced elevation of intraocular pressure. *Arch Ophthalmol* 1977;9:1075–80.
10. Garbe E, Lorier J, Boivin JF, et al. Inhaled and nasal glucocorticoids and the risk of ocular hypertension or open-angle glaucoma. *JAMA* 1997;277:722–7.
11. Cubey RB. Glaucoma following the application of corticosteroids to the skin of the eyelids. *Br J Dermatol* 1976;95:207–8.
12. Kalina RE. Increased intraocular pressure following subconjunctival corticosteroid administration. *Arch Ophthalmol* 1969;81:78–90.
13. Jonas JB, Kreissig I, Degenring R. Intraocular pressure after intravitreal injection of triamcinolone acetonide. *Br J Ophthalmol* 2003;87:24–7.
14. Beer PM, Bakri SJ, Singh RJ, et al. Intraocular concentration and pharmacokinetics of triamcinolone acetonide after a single intravitreal injection. *Ophthalmology* 2003;110:681–6.
15. Jonas JB, Degenring RF, Kreissig I, et al. Intraocular pressure elevation after intravitreal triamcinolone acetonide injection. *Ophthalmology* 2005;112:593–8.
16. Clark AF, Wilson K, McCartney MD, et al. Glucocorticoid-induced formation of cross-linked actin networks in cultured human trabecular meshwork cells. *Invest Ophthalmol Vis Sci* 1994;35:281–94.
17. Relief J, Douglas JR. Corticosteroid-induced ocular hypertension and glaucoma: a brief review and update of the literature. *Curr Opin Ophthalmol* 2006;17:163–7.
18. Jonas JB, Kreissig I, Degenring RF. Retinal complications of intravitreal injections of triamcinolone. *Graefe Arch Clin Exp Ophthalmol* 2004;42:184–8.
19. Sutter FKP, Gillies MC. Pseudoendophthalmitis after intravitreal injection of triamcinolone. *Br J Ophthalmol* 2003;87:972–4.
20. Mauricio M, Michel EF, Ruben NB, et al. Effects of intravitreal triamcinolone acetonide injection with and without preservative. *Br J Ophthalmol* 2007;91:1122–4.
21. Garcia-Arumi J, Boixadera A, Giralt J, et al. Comparison of different techniques for purification of triamcinolone acetonide suspension for intravitreal use. *Br J Ophthalmol* 2005;89:1112–4.
22. Jonas JB, Degenring RF, Kampeter BA, et al. Duration of the effect of intravitreal triamcinolone acetonide as treatment for diffuse diabetic macular oedema. *Am J Ophthalmol* 2004;138:158–60.
23. Rodriguez-Coleman H, Yuan P, Kim H, et al. Intravitreal injection of triamcinolone for diffuse macular oedema. *Arch Ophthalmol* 2004;112:1085–6.
24. Lam DSC, Chan CKM, Mohamed S, et al. A prospective randomized trial of different doses of intravitreal triamcinolone for diabetic macular edema. *Br J Ophthalmol* 2007;91:199–203.
25. Agrawal S, Agrawal J, Agrawal T. Management of intractable glaucoma following intravitreal triamcinolone acetonide. *Am J Ophthalmol* 2004;138:286–7.

# 台灣人接受玻璃體內注射康寧克通 A 之後的眼壓上升情形

張祐誠<sup>1</sup> 吳文權<sup>2,3</sup>

<sup>1</sup>高雄市立小港醫院 眼科

<sup>2</sup>高雄醫學大學附設醫院 眼科

<sup>3</sup>高雄醫學大學 醫學院醫學系 眼科

本篇研究目的在探討病人接受玻璃體內注射康寧克通 A 之後發生眼壓上升的比例以及時間點。回顧性的探討包括 52 位病人，所有的病人都接受單次玻璃體內注射 4 毫克的康寧克通 A。有意義的眼壓上升定義為術後的眼壓高於 21 毫米汞柱。本研究包含了 26 位男性以及 26 位女性。平均年齡為 59.4 歲，術前的平均眼壓以及術後的平均最高眼壓分別為 14.6 毫米汞柱以及 21.5 毫米汞柱。當中有 19 位病人 (36.5%) 在術後平均 26 天後發生了有意義的眼壓上升。而 19 位病人當中有 17 位的眼壓可以用局部青光眼藥物得到有效的控制。不論術後是否發生了有意義的眼壓上升，在玻璃體內注射 4 毫克的康寧克通 A 術後發生眼壓上升的情形是很常見的，這個現象通常發生在術後一個月左右。因此對於考慮接受這項治療的病人應該充分被告知這項副作用。

**關鍵詞：**類固醇引起之青光眼，眼內壓，玻璃體內注射，康寧克通 A

(高雄醫誌 2008;24:72-7)

收文日期：96 年 6 月 26 日

接受刊載：96 年 9 月 12 日

通訊作者：吳文權副教授

高雄醫學大學附設醫院眼科

高雄市807三民區自由一路100號