

TRANSESOPHAGEAL ECHOCARDIOGRAPHY AND LARYNGEAL MASK AIRWAY FOR PLACEMENT OF PERMANENT CENTRAL VENOUS CATHETER IN CANCER PATIENTS WITH RADIOGRAPHICALLY UNIDENTIFIABLE SVC-RA JUNCTION: EFFECTIVENESS AND SAFETY

Jong-Hau Hsu,¹ Chien-Kuo Wang,² Chueh-Wen Hung,³ Shie-Shan Wang,⁴ Kuang-I Cheng,^{3,6} and Jiunn-Ren Wu^{5,6}

Departments of ¹Pediatrics and ²Medical Imaging, Kaohsiung Medical University Hospital, Departments of ³Anesthesiology and ⁵Pediatrics, Kaohsiung Municipal Hsiao-Kang Hospital, ⁶Department of Medicine, College of Medicine, Kaohsiung Medical University, Kaohsiung, and ⁴Department of Surgery, Chang Gung Memorial Hospital, Chiayi, Taiwan.

In patients who require a permanent central venous catheter (PCVC), the usual aim is to put the catheter tip at the superior vena cava and right atrium (SVC-RA) junction. However, there is no study regarding how to guide the positioning of the catheter tip when the SVC-RA junction cannot be identified on chest radiograph. The objectives of this prospective study were: (1) to investigate the incidence and etiologies of radiographically undetermined SVC-RA junctions in cancer patients undergoing PCVC implantation; and (2) to evaluate the feasibility, effectiveness and safety of combined transesophageal echocardiography (TEE) and laryngeal mask airway (LMA) to guide the positioning of catheters during implantations in patients without this radiographic landmark. Over a 1-year study period, 83 consecutive patients with oncologic diseases who required implantation of a PCVC in a tertiary center were screened. Their preoperative chest radiographs were examined by radiologists to identify the presence of the SVC-RA junction. Patients without a radiographically identifiable SVC-RA junction were classified as cancer-related or cancer-unrelated in terms of etiology. For patients without this landmark, we used TEE with a pediatric biplane transducer and a LMA under intravenous general anesthesia during PCVC implantation to guide the positioning of the catheter tip at the SVC-RA junction. We found that in 16% (13/83) of patients, the SVC-RA junction could not be identified on radiograph. Among the 13 patients, only three (23%) had cancer-related etiologies. In all of the 13 patients, the LMA was successfully placed after the TEE transducer was inserted. No episode of air leak from the LMA was found during surgery. All had the catheter tip positioned in the anatomic SVC-RA junction under TEE guidance. In conclusion, 16% of cancer patients requiring PCVC implantation had no identifiable SVC-RA junction on chest radiograph and most causes were cancer-unrelated. In patients without a radiographically identifiable SVC-RA junction, guidance by TEE under LMA general anesthesia is a feasible, safe and effective management to position a PCVC at the SVC-RA junction.

Key Words: laryngeal mask airway, permanent central venous catheter, SVC-RA junction, transesophageal echocardiography
(*Kaohsiung J Med Sci* 2007;23:435–41)

Received: March 8, 2007

Accepted: April 13, 2007

Address correspondence and reprint requests to: Dr Kuang-I Cheng, Department of Anesthesiology, Kaohsiung Municipal Hsiao-Kang Hospital, 482 Shan-Ming Road, Kaohsiung 812, Taiwan.

E-mail: kuaich@kmu.edu.tw

Permanent central venous catheters (PCVCs) are essential for patients who require prolonged intravenous access for the administration of a wide array of agents, such as chemotherapy, total parenteral nutrition, or

other caustic agents. Data indicate that catheter tips are ideally positioned at the junction of the superior vena cava and right atrium, which anatomically correlates to the superior border of the crista terminalis [1,2]. Improper positioning of the catheter too deep in the right atrium risks cardiac tamponade, while too proximal in the high superior vena cava or innominate veins risk vascular perforation, intravascular thrombosis, and device malfunction [3–5]. Therefore, it is essential to position the tip of the PCVC accurately at the superior vena cava–right atrium (SVC-RA) junction.

The position of the SVC-RA junction is most commonly determined by chest radiography as the apex of the concave shadow formed by the superimposition of the distal SVC on the RA [6]. However, determining the border between the SVC and the RA on a chest radiograph can be challenging, as previously described in a small case series of oncologic patients where this radiographic landmark was sometimes unidentifiable [7]. In addition, there is a discrepancy between the radiographic SVC-RA junction and the anatomic SVC-RA junction as verified by magnetic resonance imaging or transesophageal echocardiography (TEE) [1,7,8]. Therefore, in patients undergoing surgery requiring TEE monitoring, TEE can be used to guide the positioning of the central venous catheter with its tip at the SVC-RA junction [2]. Even though TEE is a moderately invasive modality, a recent study showed that intravenous sedation combined with laryngeal mask airway (LMA) can provide both excellent patient comfort and optimal conditions for TEE examination [9].

To date, in cancer patients undergoing PCVC implantation, there is little data about the incidence or etiologies of unidentifiable SVC-RA junction on chest radiograph, a finding that can make catheter positioning difficult when the aim is to put the tip at the SVC-RA junction. In addition, there is no report regarding the feasibility of using TEE under LMA general anesthesia to guide the positioning of the PCVC in these patients.

Thus, the aims of this study were: (1) to determine the incidence and etiologies of radiographically unidentifiable SVC-RA junction in cancer patients requiring PCVC implantation; and (2) to evaluate the feasibility, effectiveness, and safety of using TEE with LMA to guide the positioning of these catheters during implantation.

METHODS

This study was prospectively conducted in the operating room of Kaohsiung Medical University Hospital, a tertiary medical center. Written informed consent was obtained from each patient prior to enrolment in the study. The hospital's institutional review board reviewed and approved this study.

Between August 2002 and July 2003, 87 consecutive adult cancer patients who underwent PCVC implantation were screened. The flowchart of the study protocol is summarized in Figure 1. In brief, before implantation, each patient had a standard upright chest posteroanterior X-ray with the same radiographic parameters and the film was examined by two independent radiologists to determine whether or not the SVC-RA junction could be identified. The decision was made by the consensus of the two radiologists.

The radiographic SVC-RA junction was defined as the apex of the concave shadow formed by the superimposition of the distal SVC on the RA. Only those patients with unidentifiable radiographic SVC-RA junctions were enrolled in this study. Patients with esophageal disease, which is a contraindication to TEE, were excluded. The etiologies of these cases were then classified as cancer-related or cancer-unrelated according to their radiographs and/or medical records.

In the operating room, patients without identifiable radiographic SVC-RA junctions underwent PCVC implantation through the subclavian vein, under intravenous general anesthesia. All of the patients received premedication with intramuscular atropine 0.01 mg/kg and metoclopramide 10 mg. Induction agents were administered with atracurium 0.25 mg/kg, propofol 2 mg/kg, and lidocaine 0.4 mg/kg. Pre-oxygenation for 3 minutes was performed by a mask, and then a 7.5/5.5-MHz pediatric biplane transducer (Hewlett-Packard 2500) was inserted to the mid-esophagus. With the patient's head extended, a classic LMA device was inserted using a laryngoscope-guided technique [10] by an experienced anesthesiologist. The LMA was then connected to a mechanical ventilator.

Proper LMA placement was defined as when the whole or partial vocal cord is visible on viewing from a fiberoptic bronchoscope (FOB) while the tip of the FOB is located at the distal aperture of the LMA. The duration for the insertion of the LMA was recorded. To ensure that there was no air leak from the LMA, it was manipulated to avoid audible air leak in the oral

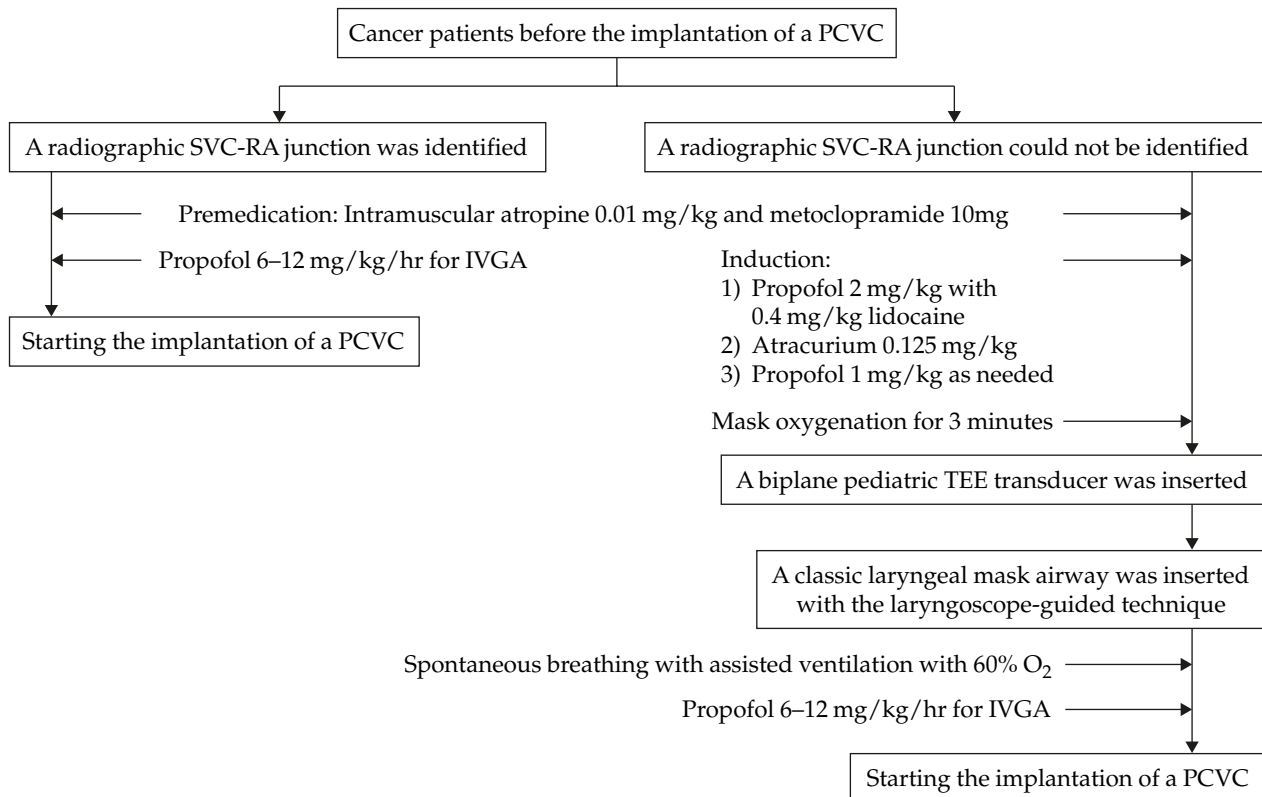


Figure 1. Flowchart of the study protocol. PCVC = permanent central venous catheter; SVC-RA = superior vena cava–right atrium; IVGA = intravenous general anesthesia; TEE = transesophageal echocardiography.

cavity during the ventilation and to show constant end tidal CO₂ plateau waveform during expiration.

After the TEE and LMA were successfully placed, propofol (6–12 mg/kg/hr) was administered intravenously for maintenance and 2% lidocaine (1 mg/kg) infiltrating anesthesia was given to prevent incision pain. The operation was then started. The PCVC implantation was performed as previously described [11]. In brief, the right or left subclavian vein was cannulated via the infraclavicular area of the anterior chest wall, just lateral to the midpoint of the clavicle. After venous access was achieved, a radio-opaque silicone catheter (single lumen, Delrin[®]; HDC Corp., Milpitas, CA, USA) was tunneled into the vessel and advanced to the SVC-RA junction with the assistance of TEE. To perform the TEE, two cardiologists experienced in perioperative TEE obtained a longitudinal view of the atria and both vena cavae in order to visualize the SVC-RA junction. The anatomic SVC-RA junction was defined by TEE as the superior border of the crista terminalis [2].

As shown in Figure 2, the catheter was recognized as several parallel, bright, echo-dense lines surrounding the darker fluid-filled lumen. The tip was identified

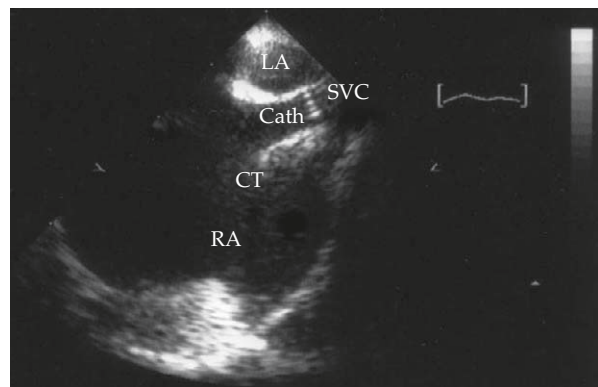


Figure 2. A central venous catheter advanced in the superior vena cava–right atrium (SVC-RA) junction shown on transesophageal echocardiography. The catheter (Cath) was advanced near the SVC-RA junction, as defined by the superior border of the crista terminalis (CT) in the right atrium (RA). LA = left atrium.

by directly visualizing the end of the venous catheter and was confirmed by hyperechogenic microbubbles quickly flowing out of the distal catheter after a rapid flush of saline.

Satisfactory positioning of a PCVC was defined as when the catheter tip is placed 0.5 cm within the

TEE-defined SVC-RA junction. After the final position of the catheter tip was adjusted to the TEE-defined SVC-RA junction, a post-insertion portable chest X-ray was taken to exclude pneumothorax or kinking of the catheter.

RESULTS

Among the 87 patients requiring PCVC implantation, there were 13 (16%) patients whose radiographic SVC-RA junctions were unidentifiable. The demographic data and etiologies of unidentifiable radiographic SVC-RA junction of these 13 patients are shown in the Table. In three patients, the etiologies were cancer-related, while in 10 patients the etiologies were cancer-unrelated. Some of the radiographs of these patients are shown in Figure 3.

In all of the 13 patients, the catheter tip was successfully placed 0.5 cm within the SVC-RA junction under TEE guidance. Proper placement of the LMA, verified by FOB, was achieved in all of the patients. The duration of inserting the LMA was 11 ± 3 seconds. In one patient, audible air leak in the oral cavity was found initially after insertion, but resolved after the positions of the LMA and the patient's head were adjusted. During PCVC implantations, no patient had air leak from the LMA.

DISCUSSION

In this study, we found that 16% of cancer patients requiring the implantation of a PCVC had SVC-RA junctions that could not be identified on radiographs, mostly due to cancer-unrelated causes. In addition, our study indicates that in patients without this landmark, TEE guidance combined with LMA under intravenous general anesthesia is a feasible, safe and effective technique to achieve the goal of putting the catheter tip at the SVC-RA junction. To our knowledge, this is the first report of PCVC implantation in patients with radiographically unidentifiable SVC-RA junctions.

Interestingly, we found that most of the etiologies of radiographically unidentifiable SVC-RA junctions were not caused by cancer even though they were all oncologic patients. This finding is important because there are possibly many more non-oncologic patients with radiographically unidentifiable SVC-RA junctions.

Table. Demographics of the 13 patients with unidentifiable superior vena cava–right atrium (SVC-RA) junction on chest radiograph*

Gender (M/F)	7/6
Age (yr)	51 ± 12
Weight (kg)	65 ± 9
Height (cm)	162 ± 14
Diagnosis	13
Gastric cancer	2
Lung cancer	2
Breast cancer	2
Colon cancer	2
Liver tumor	2
Pancreatic cancer	2
Pheochromocytoma	1
Etiologies of unidentifiable SVC-RA junction in the radiograph	
Cancer-related	3
Malignant pleural effusion	2
Pulmonary metastasis	1
Cancer-unrelated	10
Dilated or tortuous aorta	3
Elevation of right diaphragm	2
Emphysema	1
Engorged SVC	1
Fibrothorax	1
Scoliosis	1
Pneumonia	1

*Data are presented as mean ± standard deviation or *n*.

In other words, these results can be extrapolated to non-oncologic patients with chronic diseases, such as hemophilia [12], sickle cell disease [13], cystic fibrosis [14], or short-bowel syndrome [15], since PCVC implantation is often indicated in these patients due to their need for repetitive blood transfusion, prolonged antibiotics, or long-term parenteral nutrition.

To date, there are many methods used to position the tip of a PCVC at the SVC-RA junction. By convention, radiography is the most commonly used modality. In patients without an identifiable SVC-RA junction on chest radiograph, fluoroscopy may be an alternative to identify this landmark. However, many recent studies indicate the discrepancy between the anatomic and radiographic SVC-RA junction [1,7]. Aslamy et al [8] utilized magnetic resonance imaging and found that the right upper cardiac silhouette was in fact delineated by the left atrium in 38% of patients. Accordingly, the location of the SVC-RA junction shown on fluoroscopy can probably be misleading due to the confounding effect of the contour of the overlapping image of the left

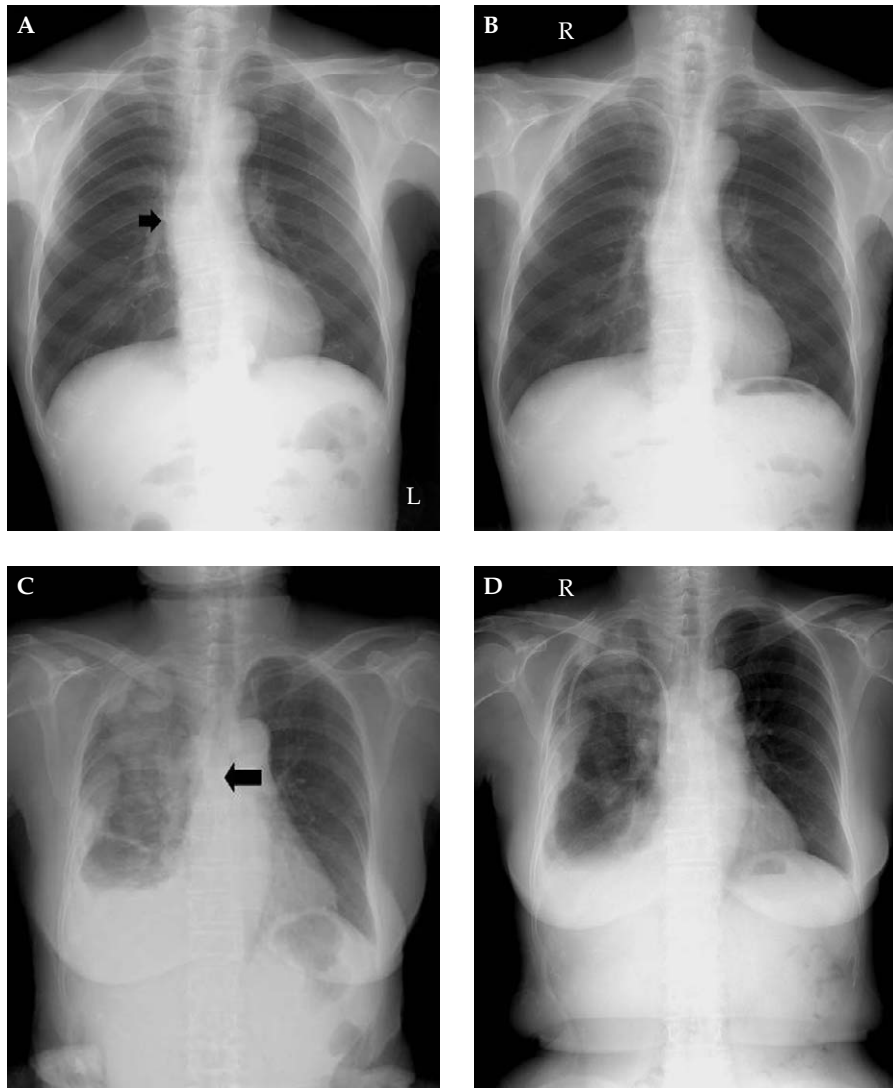


Figure 3. Perioperative chest radiographs in two patients without radiographic superior vena cava–right atrium (SVC-RA) junctions. (A) The preoperative radiograph of a patient with tortuous ascending aorta (arrow) that blunted the SVC-RA junction. (B) The postoperative radiograph of the same patient after implantation of a permanent central venous catheter. (C) The preoperative radiograph of a patient with gastric cancer and diffuse pulmonary metastasis (arrow) that blunted the SVC-RA junction. (D) The postoperative radiograph of the same patient.

atrium. Furthermore, fluoroscopy has the disadvantage of high radiation exposure to patients.

Aside from fluoroscopy, other techniques used to identify landmarks of the SVC-RA junction include skin surface landmark or vertebrae body. However, our previous study has shown that they are both unreliable references [7,11]. Another technique, intravenous electrocardiography, has also been shown to be a reliable method for guiding the position of the catheter tip in the anatomic SVC-RA junction [11]. However, this technique is not available in every hospital and some expertise is required to interpret the results.

On the other hand, TEE has been used as a standard choice for guiding the placement of a central catheter tip to the SVC-RA junction in patients during cardiac operations [1,16] because it can accurately reveal the dimensional relation between the catheter tip and the anatomic SVC-RA junction in a real-time manner. However, the role of TEE in guiding catheter tip placement in patients without cardiac disease remains to be studied. In our institution, we routinely perform the implantation of a PCVC under intravenous general anesthesia to alleviate the anxiety and pain response in cancer patients.

In this study, because of the potential side effect of TEE on airway obstruction, we simultaneously used LMA, a relatively noninvasive device compared to endotracheal tube, to establish a patent airway for mechanical ventilation during implantation surgery. In addition, we used a pediatric biplane transducer to reduce the side effect of TEE because of its shorter diameter. With this smaller transducer, we still achieved precise viewing of the SVC-RA junction and catheters in adults, even without multiplane function. Ferson et al [9] has recently shown that by the support of LMA under propofol infusion, it is safe to perform TEE in an outpatient cardiology clinic setting with an adult transducer. Therefore, it is not surprising that in our study, with continuous monitoring of cardiopulmonary function in the operating room, this technique with the combination of TEE and LMA is also safe and effective.

The most important advantage of using TEE to guide the positioning of the catheter tip is that it can accurately guide the tip to the anatomic SVC-RA junction rather than to the radiographic SVC-RA junction. This can potentially reduce the risk of cardiac tamponade when the catheter tip is too deep [6], or device malfunction when it is too high [5]. In addition, it can reduce the radiation exposure to patients, since Fricke et al [17] reported that 86% of patients receiving peripherally inserted central catheter without fluoroscopy guidance required additional manipulation by fluoroscopy to achieve a proper position of the catheter tips.

The primary limitation of this study is the sample size. Larger studies are warranted to validate the role of this combined TEE and LMA technique in patients requiring a PCVC, both in oncologic patients and non-oncologic patients. Another limitation is the lack of a control group. However, since there were no radiographic SVC-RA junctions in these patients, we could not use the conventional radiographic method as the control group in the present study.

In conclusion, our study indicates that in cancer patients with radiographically unidentifiable SVC-RA junctions, the novel technique of combined TEE and LMA is a feasible, safe and effective method to guide the catheter tip of a PCVC to the SVC-RA junction.

REFERENCES

1. Andropoulos DB, Stayer SA, Bent ST, et al. A controlled study of transesophageal echocardiography to guide

- central venous catheter placement in congenital heart surgery patients. *Anesth Analg* 1999;89:65-70.
2. Andropoulos DB. Transesophageal echocardiography as a guide to central venous catheter placement in pediatric patients undergoing cardiac surgery. *J Cardiothorac Vasc Anesth* 1999;13:320-1.
3. Collier PE, Goodman GB. Cardiac tamponade caused by central venous catheter perforation of the heart: a preventable complication. *J Am Coll Surg* 1995;181:459-63.
4. Duntley P, Siever J, Korwes ML, et al. Vascular erosion by central venous catheters. Clinical features and outcome. *Chest* 1992;101:1633-8.
5. Petersen J, Delaney JH, Brakstad MT, et al. Silicone venous access devices positioned with their tips high in the superior vena cava are more likely to malfunction. *Am J Surg* 1999;178:38-41.
6. Collier PE, Ryan JJ, Diamond DL. Cardiac tamponade from central venous catheters. Report of a case and review of the English literature. *Angiology* 1984;35:595-600.
7. Hsu JH, Wang CK, Chu KS, et al. Comparison of radiographic landmarks and the echocardiographic SVC/RA junction in the positioning of long-term central venous catheters. *Acta Anaesthesiol Scand* 2006;50:731-5.
8. Aslamy Z, Dewald CL, Heffner JE. MRI of central venous anatomy: implications for central venous catheter insertion. *Chest* 1998;114:820-6.
9. Ferson D, Thakar D, Swafford J, et al. Use of deep intravenous sedation with propofol and the laryngeal mask airway during transesophageal echocardiography. *J Cardiothorac Vasc Anesth* 2003;17:443-6.
10. van Heerden PV, Kirrage D. Large tonsils and the laryngeal mask airway. *Anaesthesia* 1989;44:703.
11. Chu KS, Hsu JH, Wang SS, et al. Accurate central venous port-A catheter placement: intravenous electrocardiography and surface landmark techniques compared by using transesophageal echocardiography. *Anesth Analg* 2004;98:910-4.
12. Ljung R, van den Berg M, Petrini P, et al. Port-A-Cath usage in children with haemophilia: experience of 53 cases. *Acta Paediatr* 1998;87:1051-4.
13. McCready CE, Doughty HA, Pearson TC. Experience with the Port-A-Cath in sickle cell disease. *Clin Lab Haematol* 1996;18:79-82.
14. Ball AB, Duncan FR, Foster FJ, et al. Long term venous access using a totally implantable drug delivery system in patients with cystic fibrosis and bronchiectasis. *Respir Med* 1989;83:429-31.
15. Naslund E, Wadstrom C, Backman L. Long term home parenteral nutrition using a subcutaneous venous access. *Clin Nutr* 1992;11:93-6.
16. Yoon SZ, Shin TJ, Kim HS, et al. Depth of a central venous catheter tip: length of insertion guideline for pediatric patients. *Acta Anaesthesiol Scand* 2006;50:355-7.
17. Fricke BL, Racadio JM, Duckworth T, et al. Placement of peripherally inserted central catheters without fluoroscopy in children: initial catheter tip position. *Radiology* 2005;234:887-92.

X 光無法辨識上腔靜脈右心房交接處的 癌症病人以喉罩通氣道及經食道心臟 超音波配合植入長期中央靜脈 導管之效果與安全性

徐仲豪¹ 王建国² 洪雀雯³ 王世憲⁴ 程廣義^{3,6} 吳俊仁^{5,6}

高雄醫學大學附設醫院 ¹小兒部 ²放射科

高雄市長小港醫院 ³麻醉科 ⁵小兒科

⁴嘉義長庚醫院 外科部

⁶高雄醫學大學 醫學院醫學系

植入長期中央靜脈導管時，導管尖端常放在上腔靜脈與右心房交接處。目前並無報告顯示，病人 X 光片無法辨識上腔靜脈右心房交接處時，放置長期中央靜脈導管，該如何定位。本前瞻性研究的目的有：(1) 需要植入長期中央靜脈導管的癌症病人，X 光片無法辨識上腔靜脈右心房交接處的發生率及原因。(2) 無法辨識此交接處之病人，在植入長期中央靜脈導管時，以喉罩通氣道 (LMA) 結合經食道心臟超音波 (TEE) 協助導管定位的可行性、有效性及安全性。研究以一年時間，篩檢醫學中心連續 83 位需要植入長期中央靜脈導管之成年癌症病人。放射線醫師先判讀病人之術前 X 光片以檢視其上腔靜脈右心房交接處可否被辨識，分類無法辨識之原因與癌症相關或非相關。對於交接處無法辨識的病人，在植入長期中央靜脈導管時，以小兒雙平面 TEE 探頭配合 LMA，於靜脈麻醉下，將導管導引至上腔靜脈右心房交接處。有 16% (13/83) 的病人無法在 X 光片辨識上腔靜脈右心房交接處，其原因只有 23% (3/13) 與癌症相關。此 13 位病人的 LMA 皆在 TEE 探頭置入後成功地放置、無漏氣情形發生，且導管尖端均成功地放置於上腔靜脈右心房交接處。結論：16% 之癌症病人無法以 X 光片辨識上腔靜脈右心房交接處，其原因大多與癌症非相關。這些病人、在 LMA 全身麻醉下，以 TEE 導引長期中央靜脈導管至上腔靜脈右心房交接處，是一個可行、安全及有效之方法。

關鍵詞：喉罩通氣道，長期中央靜脈導管，上腔靜脈右心房交接處，經食道心臟超音波
(高雄醫誌 2007;23:435-41)

收文日期：96 年 3 月 8 日

接受刊載：96 年 4 月 13 日

通訊作者：程廣義醫師

高雄市長小港醫院麻醉科

高雄市812小港區山明路482號