

UNILATERAL STEREOTACTIC POSTEROVENTRAL GLOBUS PALLIDUS INTERNUS PALLIDOTOMY FOR PARKINSON'S DISEASE: SURGICAL TECHNIQUES AND 2-YEAR FOLLOW-UP

Chun-Po Yen, Shiao-Jing Wu, Yu-Feng Su, Aij-Lie Kwan, Sheng-Long Howng, and Pang-Ying Shih¹
Departments of Neurosurgery and ¹Neurology, Kaohsiung Medical University Hospital,
Kaohsiung, Taiwan.

With the advent of levodopa (L-dopa) and the recognition of its striking effect on Parkinson's disease (PD), virtually all surgical procedures for PD ceased from the mid 1960s. However, there has been a resurgence of pallidotomy and other stereotactic procedures in the last two decades as physicians realized that most PD patients eventually face medical failure after long-term treatment with L-dopa. Nine PD patients, three men and six women, with an average age of 62 years and disease duration of 13 years underwent unilateral globus pallidus internus (GPi) pallidotomy contralateral to the side with marked akinetic symptoms and drug-induced dyskinesia. All patients were evaluated using the Unified Parkinson's disease Rating Scale (UPDRS) after drug withdrawal and while taking their optimal medical regimen, preoperatively and 6, 12, and 24 months after surgery. There was significant improvement in activities of daily living and motor subscores as well as total UPDRS score in the "off" state at the 2-year follow-up, which mainly resulted from improvement in contralateral bradykinesia and rigidity. Significant improvements in contralateral akinetic symptoms and drug-induced dyskinesia were also observed in the "on" state and were sustained for at least 2 years. Ipsilateral and axial symptoms were not altered by unilateral GPi pallidotomy. The complications of surgery were generally well tolerated. One patient had a small postoperative asymptomatic hemorrhage identified by routine follow-up magnetic resonance imaging. Another two patients developed temporary sexual disinhibition and auditory hallucination, respectively, which resolved spontaneously 2 weeks after surgery. The effect of pallidotomy for alleviation of akinetic parkinsonism is modest but significant, and continues to be effective for at least 2 years. Further analytical studies, especially the correlation of clinical effects and lesion locations, are important not only to provide direct feedback for surgeons to examine the technical accuracy and but also to facilitate understanding of the pathophysiology of PD.

Key Words: globus pallidus, Parkinson's disease, pallidotomy, stereotactic surgery
(*Kaohsiung J Med Sci* 2005;21:1-8)

Pallidotomy originated from incidental ligation of the anterior choroidal artery [1] and was replaced by thalamotomy due to its suboptimal effect on tremor [2]. Its use finally ground to a complete standstill after the introduction

of levodopa (L-dopa), but pallidotomy has attracted renewed interest for the treatment of Parkinson's disease (PD) in the last two decades since Laitinen et al reported successful experience with Leksell's posteroventral globus pallidus internus (GPi) lesioning [3].

Several developments are responsible for the renewed interest in surgical treatment of PD. First, although a striking response is usually observed after initial L-dopa treatment, with progression of the illness and chronic medical treatment, the response to L-dopa is less predictable and

Received: May 24, 2004 Accepted: December 2, 2004
Address correspondence and reprint requests to: Dr. Pang-Ying Shih,
Department of Neurology, Kaohsiung Medical University Hospital,
100 Tzyou 1st Road, Kaohsiung 807, Taiwan.
E-mail: waywayyen@yahoo.com.tw

less sustained, leading to wide spontaneous and dose-related fluctuations in motor function (the on-off phenomenon). Over time, the "off" period will increase and patients usually develop drug-induced involuntary movement (dyskinesia) during the "on" period. In addition, anti-parkinsonian drugs can bring psychiatric or cognitive complications. Second, advances in stereotactic techniques as well as neuroimaging and neurophysiologic monitoring have made functional neurosurgical procedures more accurate and safer. Third, the pathophysiology and the neuronal substrates responsible for the symptoms characterizing PD, namely bradykinesia, rigidity, and tremor, are now better understood. Studies in a nonhuman primate model of PD induced by methyl-phenyl-tetrahydropyridine (MPTP) provide a strong rationale for pallidotomy and other surgical strategies.

PD patients with tremor-dominant parkinsonism at Kaohsiung Medical University Hospital undergo stereotactic ventral intermediate (Vim) thalamotomy, while most patients, who present with akinetic-rigid symptoms as well as drug-induced dyskinesia with or without tremor, are treated with pallidotomy. Nine PD patients undergoing unilateral pallidotomy with complete 2-year follow-up were included in this study. We present our surgical techniques in detail as well as the clinical outcomes and operative complications.

PATIENTS AND METHODS

Patient selection

In cooperation with a movement disorder neurologist, we began performing stereotactic neurosurgery at our institute in 1999. Patients with idiopathic PD in later stages who have failed medical therapy and have reached a level of impairment in activities of daily living (ADL) are referred to our surgical team. However, end-stage patients who are bed-bound or have significant cognitive or psychiatric problems unlikely to benefit from surgery are not offered surgical treatment. We initially chose patients with asymmetric appendicular parkinsonian symptoms. Nine PD patients who underwent unilateral GPi pallidotomy from July 1999 to July 2001 and had complete follow-up data were included in this study. For the sake of congruity, patients who underwent unilateral pallidotomy and thereafter contralateral thalamotomy or pallidotomy were not included. Patients included in the study had significant parkinsonian symptoms with Hoehn and Yahr staging of 3.8 ± 0.4 during the "off" period and were experiencing

dyskinesia during the "on" period despite appropriate pharmacotherapy.

Clinical evaluation

Assessments were conducted by a neurologist before surgery (baseline) and at 6, 12, and 24 months after pallidotomy. Based on the Core Assessment Program for Intracerebral Transplantation definition, all patients were scored after a 12-hour drug-free period to assess the worst "off" state and 1–2 hours after their usual morning medications to evaluate the best "on" state.

Clinical evaluation was carried out by means of the Unified Parkinson's Disease Rating Scale (UPDRS). Modified Hoehn and Yahr staging was assessed and minimal mental status evaluation (MMSE) was also used to evaluate the cognitive effect of the surgery [4]. Subcomponents of the motor subset in UPDRS were used to study the effects of unilateral pallidotomy on ipsilateral and contralateral bradykinesia, rigidity, and tremor. All items of the motor subset in which laterality was not specified were grouped under the general denomination of axial symptoms. Doses of anti-parkinsonian medications were also evaluated before and after surgery; postoperative anti-parkinsonian medications were generally maintained at the preoperative levels, although some patients reduced their dose due to improved condition in the early postoperative period.

Target determination

Medications were withheld overnight before surgery to ensure the patient was in a relative "off" state to minimize involuntary movement during imaging and to assess the clinical effects of pallidotomy during surgery. After the Leksell stereotactic frame was applied to the patient's head, two magnetic resonance imaging (MRI) sets were obtained. Volumetric gradient echo T1-weighted images (T1WIs), covering the whole brain in 2 mm axial slices, were obtained for indirect targeting. Axial T2WIs were obtained using 2 mm non-overlapping slices through the basal ganglia for direct visualization of the target. Target coordinates were determined with the assistance of Leksell Surgiplan (Elekta, Atlanta, GA, USA), in which images can be fused and reformatted to parallel the anterior commissure–posterior commissure (AC–PC) plane and displayed in different orthogonal views. The initial target was chosen to be 3 mm anterior to the mid-commissural point, 5 mm below the AC–PC line, and 19–22 mm lateral to the midline (more lateral for patients with a larger third ventricle) according to atlas-based coordinates on T1WI. Adjustments were then made depending on direct visualization of the GPi in

relation to the internal capsule on the axial plane and to the optic tract on the coronal plane according to T2WIs, which were fused with volumetric images. In a minority of cases where the outer border of the GPi could not be well delineated, a resident digitized atlas helped to check the target position in various planes and the placement of the target was adjusted if necessary.

Surgical procedure

Once the target coordinates were obtained, the patient was transferred to the operating theater. Under local anesthesia, a burr hole was placed 3 cm lateral to the midline at the coronal suture contralateral to the side with the most disabling symptoms. Macrostimulation was performed using an electrode introduced to a point 6 mm above the planned target and then moved deeper by 2 mm intervals. Low-frequency stimulation was used to obtain the motor threshold and high-frequency stimulation was used to assess proximity to the optic tract. The target was adjusted if necessary to put it posteriorly and ventrally enough but not to cause injury to the internal capsule and optic tract. High-frequency macrostimulation was also used to test the amelioration of PD symptoms by checking the rigidity of the joint and asking patients to perform finger or foot tapping and rapid pronation and supination of the forearm. Speech function was also evaluated from volume, articulation, and fluency. Facial contraction or finger movement under low current amplitude meant that the target was too close to the internal capsule and vice versa. Phosphenes observed by patients provided important information on the relationship between the target and the optic tract. In four of nine patients, we were not able to elicit this phenomenon and the placement of the target was guided by motor responses and relief of symptoms. Adjustments of the final target were determined after integrating information about alleviation of symptoms and undesired effects. The number of trajectories used to define the best target point ranged between two and four. Once the target was determined, a test lesion was made using radiofrequency thermocoagulation (60°C, 60 seconds) with a thermocoupled stereotactic electrode. If no undesired effect was detectable after repeating the motor, visual and speech tests, final lesions were created using 80°C for 80 seconds at the target point and repeated 2 and 4 mm above (Figure 1).

Statistical analysis

Statistical analyses were carried out using SPSS version 10.1 (SPSS Inc, Chicago, IL, USA). Pre- and postoperative

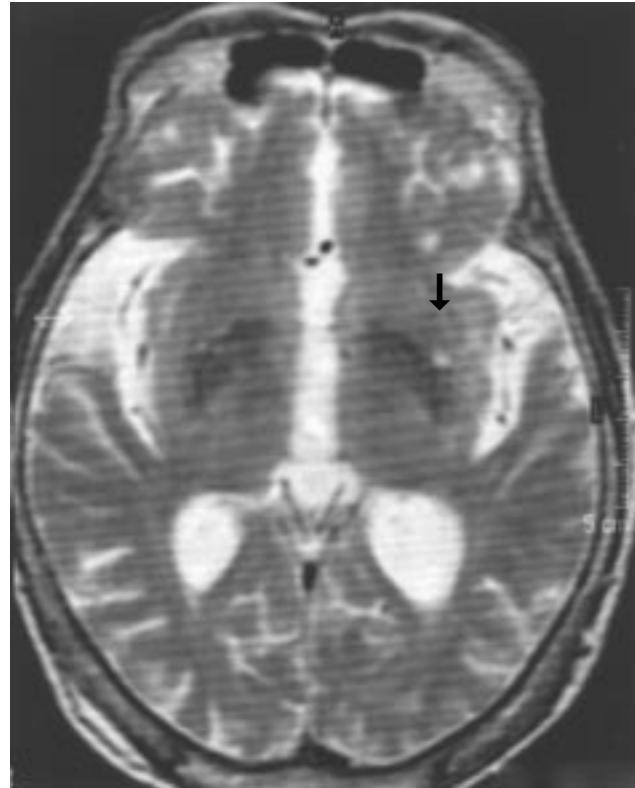

Figure 1. Unilateral lesion on the left posteroventral globus pallidus internus (black arrow).

scores were analyzed by means of pair-wise comparisons using the Wilcoxon signed rank test for each variable. To evaluate the possible changes over time, all variables were studied using analysis of variance (ANOVA) with repeated measures, where the repeated measure was the interval between clinical assessments. All statistical analyses were performed with two-tailed probability; an alpha level of p less than 0.05 was used to determine significance.

RESULTS

Three males and six females with a mean age of 62 years (range, 46–82 years) and disease duration of 13 years (range, 9–17 years) were included in the study. Unilateral posteroventral pallidotomy was performed on the left side in three patients and on the right side in six. Baseline Hoehn and Yahr staging in the “off” state was 3.8 ± 0.4 (range, 3–5) (Table 1). The MMSE score was within the normal range. Other clinical baseline characteristics including UPDRS scores and subscores in “off” and “on” states are depicted in Tables 1 and 2.

Table 1. Mean “off” scores at baseline and at 6 and 12 months and 2 years after surgery

Scale	Score	Baseline	6 months	12 months	2 years	<i>p</i> *
Hoehn and Yahr	1–5	3.8 ± 0.4	2.8 ± 0.7	3.2 ± 0.7	3.3 ± 0.5	0.102
UPDRS total	0–176	58.7 ± 13.6	38.2 ± 11.1	44.2 ± 12.9	46.3 ± 12.7	0.036
UPDRS-1	0–16	3.6 ± 1.5	3.2 ± 1.0	4.7 ± 2.1	4.8 ± 2.3	0.157
UPDRS-2	0–52	17.4 ± 6.6	9.6 ± 5.1	11.0 ± 7.0	11.0 ± 6.1	0.015
UPDRS-3	0–108	37.7 ± 10.1	25.4 ± 8.5	28.6 ± 7.3	30.6 ± 7.8	0.028
Axial symptoms	0–36	12.7 ± 4.8	11.0 ± 6.7	11.3 ± 4.0	11.6 ± 4.5	0.550
Ipsilateral						
Bradykinesia	0–16	5.8 ± 2.9	4.3 ± 1.7	5.8 ± 2.5	6.1 ± 1.8	0.776
Rigidity	0–8	2.7 ± 1.2	1.4 ± 1.1	1.7 ± 1.5	2.0 ± 1.8	0.236
Tremor	0–12	1.7 ± 1.3	1.6 ± 1.3	2.3 ± 2.1	2.6 ± 2.6	0.190
Contralateral						
Bradykinesia	0–16	8.7 ± 3.3	4.3 ± 2.2	4.0 ± 2.1	4.7 ± 2.1	0.012
Rigidity	0–8	3.2 ± 1.4	1.3 ± 1.0	1.3 ± 1.1	1.6 ± 1.2	0.014
Tremor	0–12	3.0 ± 2.2	1.3 ± 1.0	2.0 ± 2.4	1.9 ± 2.1	0.087

*Between baseline and 2-year assessment, using Wilcoxon signed rank test. Data are presented as mean scores ± standard deviation; lower scores indicate better function. UPDRS = Unified Parkinson's Disease Rating Scale.

Table 2. Mean “on” scores at baseline and at 6 and 12 months and 2 years after surgery

Scale	Score	Baseline	6 months	12 months	2 years	<i>p</i> *
Hoehn and Yahr	1–5	3.1 ± 0.5	2.6 ± 0.5	2.8 ± 0.4	2.9 ± 0.5	0.257
UPDRS-total	0–176	45.0 ± 9.5	30.4 ± 7.9	35.2 ± 12.5	41.1 ± 13.7	0.373
UPDRS-1	0–16	2.9 ± 0.9	2.6 ± 0.7	4.3 ± 2.4	4.4 ± 2.4	0.048
UPDRS-2	0–52	14.7 ± 5.2	8.7 ± 4.8	9.3 ± 5.4	11.6 ± 5.3	0.205
UPDRS-3	0–108	27.4 ± 6.6	19.2 ± 5.4	21.6 ± 7.3	25.1 ± 9.0	0.261
Axial symptoms	0–36	7.6 ± 3.1	6.4 ± 3.7	7.1 ± 3.7	7.8 ± 4.9	1.0
Dyskinesia	0–12	4.2 ± 1.6	1.1 ± 1.1	1.3 ± 1.7	1.8 ± 1.9	0.015
Ipsilateral						
Bradykinesia	0–16	4.3 ± 2.3	3.0 ± 1.2	3.8 ± 2.3	4.8 ± 2.1	0.340
Rigidity	0–8	2.0 ± 0.9	1.1 ± 0.9	1.2 ± 1.2	1.3 ± 1.5	0.230
Tremor	0–12	1.4 ± 1.1	1.2 ± 1.1	1.7 ± 1.0	2.3 ± 1.0	0.038
Contralateral						
Bradykinesia	0–16	6.7 ± 2.7	4.1 ± 2.0	3.6 ± 1.9	4.3 ± 2.3	0.011
Rigidity	0–8	2.4 ± 0.5	1.1 ± 0.8	1.2 ± 1.1	1.3 ± 1.0	0.023
Tremor	0–12	3.0 ± 2.1	2.2 ± 1.6	3.0 ± 2.2	3.2 ± 2.4	0.414

*Between baseline and 2-year assessment, using Wilcoxon signed rank test. Data are presented as mean scores ± standard deviation; lower scores indicate better function. UPDRS = Unified Parkinson's Disease Rating Scale.

“Off” state evaluation at 2-year follow-up

In the “off” state, ADL and motor scores improved significantly at 2-year follow-up by 21% and 18%, respectively (Table 1). Changes in UPDRS scores are illustrated in Figure 2. The improvement in motor score was mostly due to improvement in bradykinesia (46%) and rigidity (52%) on the side contralateral to pallidotomy. Although the subscore for contralateral tremor also improved by 40%, this was not statistically significant. Ipsilateral motor symptoms seemed to have progressed by the 2-year follow-up (not statistically significant),

except for rigidity. The Hoehn and Yahr staging, UPDRS subset I (mentation, behavior, and mood), and axial symptoms did not change significantly.

“On” state evaluation at 2-year follow-up

During the “on” period, there was sustained improvement in contralateral bradykinesia and rigidity, which we attributed to better compliance with medications due to elimination of drug-induced dyskinesia (Table 2). Ipsilateral motor symptoms did not improve and even worsened with time, which was especially evident for tremor. Drug-

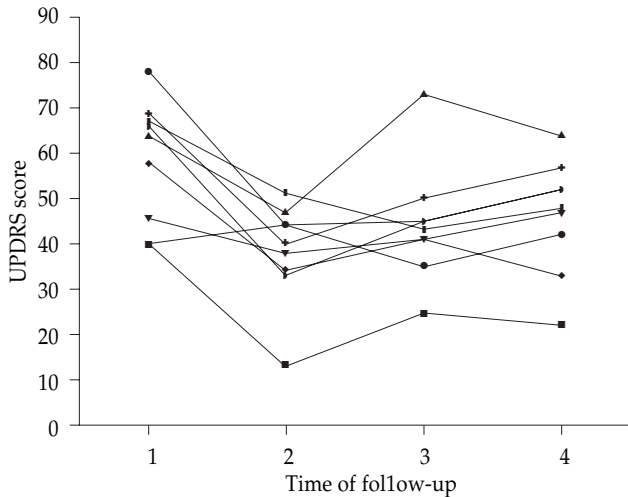


Figure 2. Changes in Unified Parkinson's Disease Rating Scale (UPDRS) scores among nine patients undergoing unilateral pallidotomy. 1 = baseline; 2 = 6 months; 3 = 12 months; 4 = 2 years.

induced dyskinesia improved significantly by 57%. ADL and motor scores as well as axial symptoms did not change significantly in the "on" state. There was significant worsening of the subset I score.

Comparison between 6- and 12-month and 2-year follow-up

In the "off" state, subscores for contralateral bradykinesia and rigidity as well as ADL and motor symptoms improved significantly at the first follow-up and this was sustained until the last follow-up (Figure 3). There was no significant effect on axial symptoms after the first evaluation. Contralateral tremor was improved at 6 months and ipsilateral rigidity was improved at 6 and 12 months of follow-up, but the effects waned thereafter (Figure 4).

In the "on" state, contralateral bradykinesia and rigidity improved initially, which persisted for 2 years (Figure 5). Significant improvements in contralateral tremor and ipsilateral bradykinesia were observed at the first follow-up but lost between 6 and 12 months. The improvement in motor score was observed at the first two follow-ups but became insignificant due to worsened ipsilateral symptoms. Improvement in ADL at the first and second follow-ups also waned at the last follow-up. Axial symptoms did not change over time. Of note, there was significant deterioration in the subscore for mentation, behavior, and mood at the 12-month follow-up. Dyskinesia remained markedly improved for at least 2 years.

Complications

No patients presented with motor weakness or visual field

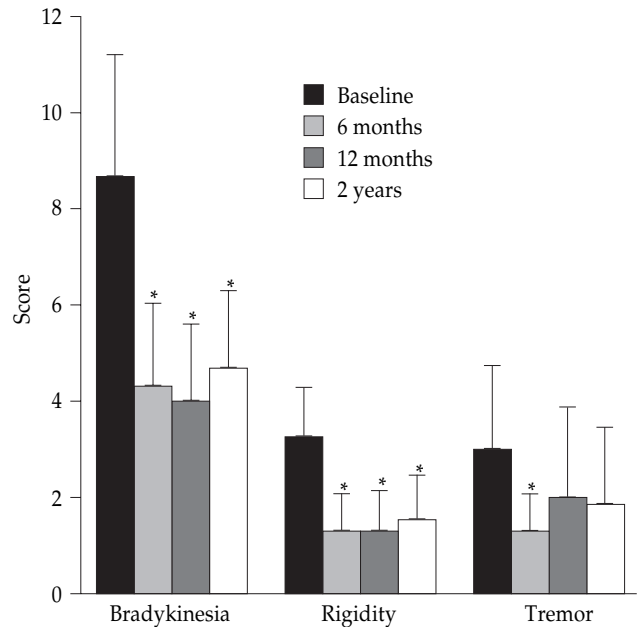


Figure 3. "Off" period scores for contralateral bradykinesia, rigidity, and tremor. *p < 0.05 baseline versus different follow-up evaluations.

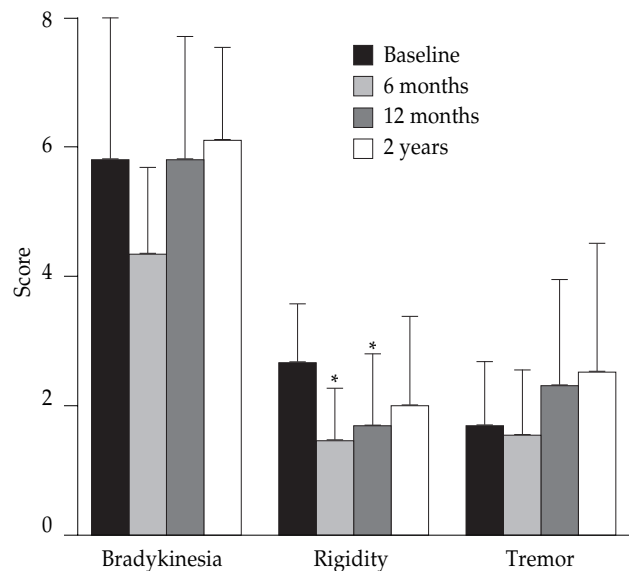


Figure 4. "Off" period scores for ipsilateral bradykinesia, rigidity, and tremor. *p < 0.05 baseline versus different follow-up evaluations.

defects. One patient had a small, asymptomatic subclinical hemorrhage at the lesion site, which was found during routine postoperative follow-up MRI. One patient presented with sexual disinhibition and another with auditory hallucination following pallidotomy. The symptoms resolved spontaneously within 2 weeks after surgery. Follow-up MRI showed optimal target location without

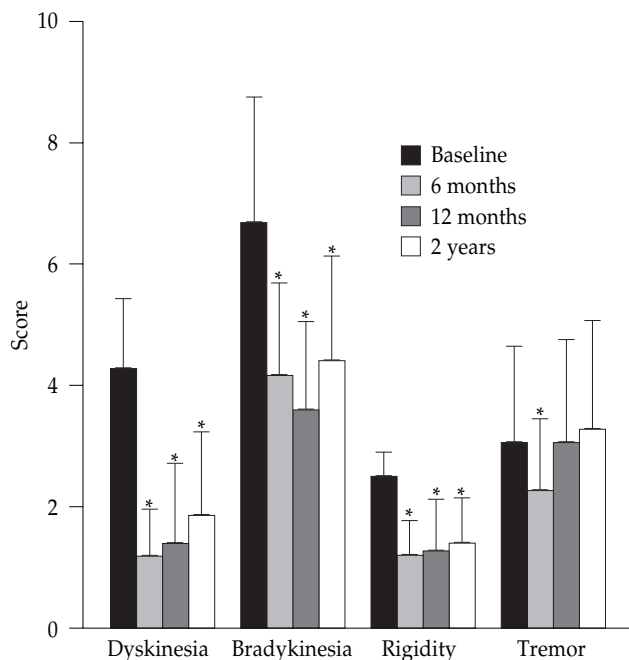


Figure 5. "On" period scores for dyskinesia, contralateral bradykinesia, rigidity, and tremor. * $p < 0.05$ baseline versus different follow-up evaluations.

other abnormality. Four patients experienced obvious weight gain; the mechanism was unclear, although neuropsychologic factors and elimination of dyskinesia have been reported to be related [5]. All patients showed significant improvement in symptoms accompanied by better ADL and appetites according to family observations.

Due to the small number of cases and great variation in educational level, extensive neuropsychologic assessment could not be done properly. According to evaluation with MMSE and UPDRS subset I, patient's mentality seemed to deteriorate. We were unable to draw a conclusion about whether the deterioration was a result of the natural course of PD or pallidotomy.

DISCUSSION

Disturbance in the basal ganglia, particularly hyperactivity of the GPi and subthalamic nucleus (STN) resulting from dopamine deficiency, produces excessive inhibitory outflow to the thalamus which, in turn, prevents the downstream regulation of the motor cortex leading to the disordered and impoverished movement in PD. The overactivity of the GPi and STN in the pathophysiology of parkinsonism has been identified via a nonhuman primate model and is supported by the observations that lesions or delivery of electric current

to these targets ameliorate parkinsonian symptoms in MPTP-treated monkeys as well as PD patients. Using functional imaging, reversal of diminished activation in the supplementary motor area and premotor area has been reported in PD patients after GPi pallidotomy [6].

Considerable data are now accumulating to support the efficacy of posteroventral GPi pallidotomy in later-stage PD [7–9]. In general, most studies agree that pallidotomy has a pronounced effect on L-dopa-induced dyskinesia and cardinal motor dysfunction in "off" state parkinsonism contralateral to the side of surgery. Our results are compatible with other groups' reports showing long-term significant improvement in contralateral bradykinesia and rigidity [7–10]. The elimination of L-dopa-induced dyskinesia enabled us to use anti-parkinsonian medications more liberally and increased patients' drug compliance, which in turn contributed to improve "on" state bradykinesia and rigidity. Alleviation of contralateral tremor was not significant, which we attributed to the small number of cases and the bias due to selection of akinesia-dominant PD patients with fewer tremor symptoms (6 patients with contralateral tremor scores ≤ 3 during the "off" period). Global improvement was obvious according to "off" state total UPDRS score as well as ADL and motor subscores, and persisted for at least 2 years. Axial symptoms, which can be improved by unilateral surgery [10], were not obviously improved in our patients. The surgical benefits on the ipsilateral side, apart from some short-term effects on rigidity, were neither marked nor sustained, which is consistent with other reports in the literature [8].

Unlike the STN, whose boundary is difficult to delineate using modern imaging techniques, targeting the most medial, ventral, and posterior part of the GPi can be achieved using MRI. Traditionally, the target of pallidotomy has been defined based on the stereotactic atlas. The atlas method, defining targets in reference to the AC–PC line, is more consistent for those lying not far from the midline such as the STN or Vim of the thalamus. The GPi, which is the farthest target from the third ventricle, presents with widest variation between each individual and even from side to side of the same brain [11]. Changing the MRI parameters enhances the boundary between the GPi and the posteromedial internal capsule and underneath the optic tract. Using planning software with reconstructed images at different planes helps to determine the lesion location and correct the errors caused by improper placement of the frame. A built-in deformable atlas also facilitates delineation of the border of the GPi in unusual cases where the GPi cannot be seen properly by adjusting

the MRI acquisition parameters.

The role of microelectrode recordings in the localization of the STN is generally accepted, but its role in pallidotomy is still under debate [12,13]. The aim of microelectrode recordings is to provide physiologic data about the selected target as well as its surroundings, thereby optimizing creation of the lesion. Anatomic-functional dissociation of the target, brain shift during surgery, and imaging inaccuracies are the basic considerations calling for physiologic corroboration by microelectrode recordings. However, high-quality images provided by new MRI techniques and physiologic data from intraoperative macrostimulation using the patient's response to stimulation have solved most of the problems. Many groups have reported comparable results with pallidotomy without the aid of microelectrode recordings [9,12]. Even though more information can be derived from microelectrode recordings, it is not without complications. A higher incidence of hemorrhage has been reported and cost-effectiveness is another consideration due to the requirement for expensive instruments, trained personnel, and tedious evaluation with prolonged operation time.

As knowledge about the pathophysiology of basal ganglia and the clinical outcome data of various surgical procedures become available, preference for different surgical targets and a more rational treatment approach should emerge. Bilateral pallidotomy is supposed to benefit PD patients with bilateral and axial disability. Scott et al have reported a 53% improvement in UPDRS score in patients undergoing bilateral pallidotomy compared to 27% improvement after unilateral surgery [14]. However, the higher incidence of complications such as speech dysfunction and cognitive deterioration should be kept in mind when selecting bilateral ablative procedures [15]. Recently, interest has been shifted to deep brain stimulation (DBS). The advantage of DBS is its non-destructive and adaptable nature. Although the mechanism of DBS is not well understood, functional images have shown that GPi stimulation, like pallidotomy, reduces excessive inhibition of the thalamocortical circuit. However, wide-scale use is not a practical option so far considering the limited health care resources and lack of long-term results. Lesioning at the STN to influence the entire output of the basal ganglia (GPi and substantial nigra par reticulata) could be a promising alternative, but the procedure necessitates a much more delicate approach by experienced hands because of the high incidence of worrisome hemiballism.

In conclusion, posteroventral GPi pallidotomy has substantial and long-term effects on contralateral

parkinsonism during "off" and "on" periods, which improves PD patients' motor activity. The effect on dyskinesia is also marked and sustained. There was no measurable benefit for axial and ipsilateral symptoms in our series. Further evaluations, especially of the location and size of the ablative lesion and its correlation with clinical outcome, would not only give surgeons feedback, enabling refinement of the surgical techniques, but also provide important pathophysiologic insights into PD.

REFERENCES

1. Cooper IS. Ligation of the anterior choroidal artery for involuntary movements of parkinsonism. *Psychiatr Q* 1953;27:317-9.
2. Hassler R, Reichert T. Indications and localization of stereotactic brain operations. *Nervenarzt* 1954;25:441-7. [In German]
3. Laitinen LV, Bergenheim AT, Hariz MI. Leksell's posteroventral pallidotomy in the treatment of Parkinson's disease. *J Neurosurg* 1992;76:53-61.
4. Hoehn MM, Yahr MD. Parkinsonism: onset, progression and mortality. *Neurology* 1967;17:427-42.
5. Lang AE, Lozano AM, Tasker R, et al. Neuropsychological and behavior changes and weight gain after medial pallidotomy. *Ann Neurol* 1997;41:834-6.
6. Ceballos-Baumann AO, Obeso JA, Vitek JL, et al. Restoration of thalamocortical activity after posteroventral pallidotomy in Parkinson's disease. *Lancet* 1994;344:814.
7. Alterman RL, Kelly PJ. Pallidotomy technique and results: the New York University experience. *Neurosurg Clin North Am* 1998;9:337-43.
8. Lang AE, Lozano AM, Montgomery E, et al. Posteroventral medial pallidotomy in advanced Parkinson's disease. *N Engl J Med* 1997;337:1036-42.
9. Eskandar EN, Shinobu LA, Penny JB Jr, et al. Stereotactic pallidotomy performed without using microelectrode guidance in patients with Parkinson's disease: surgical technique and 2-year results. *J Neurosurg* 2000;92:375-83.
10. Lozano AM, Lang AE, Galvez-Jimenez N, et al. Effect of GPi pallidotomy on motor function in Parkinson's disease. *Lancet* 1995;346:1383-7.
11. Hirabayashi H, Tengvar M, Hariz MI. Stereotactic imaging of the pallidal target. *Mov Disord* 2002;17(Suppl 3):S130-40.
12. Carroll CB, Scott R, Davies LE, et al. The pallidotomy debate. *Br J Neurosurg* 1998;12:146-50.
13. Lozano AM, Hutchison WD. Microelectrode recordings in the pallidum. *Mov Disord* 2002;17(Suppl 3):S150-4.
14. Scott R, Gregory R, Hines N, et al. Neuropsychological, neurological and functional outcome following pallidotomy for Parkinson's disease. A consecutive series of eight simultaneous bilateral and twelve unilateral procedures. *Brain* 1998; 121:659-75.
15. Giller CA, Dewey RB, Ginsburg MI, et al. Stereotactic pallidotomy and thalamotomy using individual variations of anatomical landmarks for localization. *Neurosurg* 1998;42:56-62.

單側立體定位蒼白球後腹側燒灼術 治療帕金森氏症 — 手術方法及兩年追蹤

顏俊博¹ 吳曉臻¹ 蘇裕峯¹ 關禮麗¹ 洪純隆¹ 施邦英²

高雄醫學大學 附設中和紀念醫院 ¹神經外科 ²神經內科

自從一九六十年代末期左多巴氨被使用於治療帕金森氏症病患以來，它的顯著效果使得所有手術治療方法幾乎完全停頓。然而，近二十年來，手術治療帕金森氏症又再度興起，其主要原因乃是帕金森氏症病患經過長期左多巴氨治療後大多逐漸失去反應並出現嚴重的副作用。本研究包括九位帕金森氏症病患，其中男性三人，女性六人，平均年齡六十二歲，罹患帕金森氏症平均十三年，針對較嚴重肢體症狀之對側分別施以單側立體定位蒼白球燒灼術。病患分別在停藥及服藥後接受帕金森氏症評量表之評估，評估時間分別在手術前及術後第六、第十二及第二十四個月。針對評量表中停藥狀態下，日常生活和運動狀況的分數及總分在手術後兩年評估時，病患仍有顯著的進步，而這進步主要來自於對側運動遲緩及僵硬症狀的改善。至於在服藥狀態下，運動遲緩、僵硬及藥物引起的運動不能也顯示有意義的改善。基本上，身體軸及手術同側的症狀則無明顯的進步。手術引起的併發症並不顯著。一位病患在術後核磁共振檢查發現小出血，但臨床上並無症狀，另有兩位病人分別出現性慾過度及幻聽，但都在術後二週內消失。對於中、晚期的帕金森氏症病患，立體定位蒼白球燒灼術可以提供病患在運動症狀上相當程度的緩解，且效果可以持續兩年以上。對這些病患的進一步追蹤分析非常重要，尤其是確實的手術燒灼位置與相對的臨床症狀改善程度，因為這不但在臨床上讓手術醫師了解其手術的準確性，在基礎研究上也幫忙我們進一步了解帕金森氏症的生理病理機轉。

關鍵詞：蒼白球，巴金森氏症，蒼白球切開術，立體定位手術
(高雄醫誌 2005;21:1-8)

收文日期：93年5月24日

接受刊載：93年12月2日

通訊作者：施邦英醫師

高雄醫學大學附設中和紀念醫院神經內科

高雄市三民區自由一路100號