

DIFFERENTIATION AMONG METASTATIC BRAIN TUMORS, RADIATION NECROSES, AND BRAIN ABSCESSES USING PROTON MAGNETIC RESONANCE SPECTROSCOPY

Yan-Fen Hwang, Tzuu-Yuan Huang,¹ Shiuh-Lin Hwang,
Aij-Lie Kwan, and Shen-Long Howng

Department of Neurosurgery, Kaohsiung Medical University Hospital, and

¹Department of Surgery, Kaohsiung Municipal United Hospital, Kaohsiung, Taiwan.

Magnetic resonance imaging (MRI) and proton magnetic resonance spectroscopy (MRS) were evaluated for differentiating metastatic brain tumors, radiation necroses, and brain abscesses. Twelve histologically verified lesions in 12 patients were studied using preoperative MRI and proton MRS. The signal intensities of four major metabolites, N-acetyl aspartate (NAA), choline-containing compounds (Cho), creatine and phosphocreatine (Cr), and lactate (Lac), were observed over the region of interest. Metastatic brain tumors showed a decrease in NAA/Cr and an increase in Cho/Cr ratios. Radiation necroses showed a decrease in NAA/Cr and no change in Cho/Cr ratios. Brain abscesses showed an increase in Lac/Cr ratio. Correlation with histopathologic findings showed that a high Cho signal was suggestive of a metastatic brain tumor. Lac signals were observed in brain abscesses, presumably reflecting the anaerobic glycolysis of living cells. Although more cases and studies are necessary, metabolic information provided by proton MRS combined with MRI is useful for differentiating among metastatic brain tumors, radiation necroses, and brain abscesses.

Key Words: magnetic resonance imaging, magnetic resonance spectroscopy, metastatic brain tumor, radiation necrosis, brain abscess
(*Kaohsiung J Med Sci* 2004;20:437-42)

The radiologic assessment of brain lesions is very important in determining treatment strategy. Radiotherapy with or without surgical resection is now the most common treatment for malignant brain tumors. Post-radiation necrosis should be distinguished from recurrent brain tumors, so that radiosurgery or subsequent surgical intervention can be considered [1]. In addition, treating cerebral abscesses, which mimic tumors, could be rendered ineffective if an improper diagnosis is made. Several methods for differentiation between recurrent brain tumors and post-radiation necroses have been introduced,

including positron emission tomography [2,3], ²⁰¹Tl single photon emission tomography [2], magnetic resonance imaging (MRI) [3], and stereotactic biopsy [3,4]. Proton magnetic resonance spectroscopy (MRS) has been studied in metabolic characterization of the human central nervous system since the 1990s [5-7], and even used for prognosis prediction in 2003 [8]. This diagnostic method could be widely accessible and not too expensive [9]. This method was compared with histopathologic diagnosis to examine the accuracy of a preoperative diagnosis using proton MRS combined with MRI.

Received: April 23, 2004

Accepted: May 28, 2004

Address correspondence and reprint requests to: Dr. Shen-Long Howng, Department of Neurosurgery, Kaohsiung Medical University Hospital, 100 Tzyou 1st Road, Kaohsiung 807, Taiwan.

E-mail: slhowng@cc.kmu.edu.tw

PATIENTS AND METHODS

Twelve patients (9 men, 3 women; mean age, 55 years; age range, 35-85 years) with brain lesions underwent surgical

intervention after preoperative MRI and proton MRS. Postoperative histopathologic diagnoses were compared with preoperative diagnosis by proton MRS combined with MRI. Multislice fast spin-echo MR images in the sagittal, coronal, and transverse (slice thickness, 5 mm) planes were obtained to locate the region of interest (ROI) for spectroscopy [8,9]. The ROI was chosen to include the lesion center and surrounding brain tissue. MRI and proton MRS from normal brains were also studied. Control data were obtained from the temporal regions in healthy normal brains and from the ROIs selected to contain adjacent normal brain tissue in the 12 cases. MRS peak concentrations of four metabolites were observed: for choline-containing compounds (Cho) at 3.2 ppm; creatine and phosphocreatine (Cr), 3.0 ppm; N-acetyl aspartate (NAA), 2.0 ppm; and lactate (Lac), 1.3 ppm [5–10]. Peak concentrations of NAA, Cr, and Cho were also observed in controls. Lac could not be seen in normal brain tissue. The ratios of NAA/Cr, Cho/Cr, and Lac/Cr were calculated.

RESULTS

Four patients with a marked decrease in NAA/Cr and an increase in Cho/Cr were diagnosed with metastatic brain tumors, which was verified by histopathologic diagnosis. Three patients with malignant brain tumors after radiotherapy (who were investigated to determine whether this was recurrent) had a decrease in NAA/Cr and no change in Cho/Cr, and were diagnosed as having radiation necrosis, which was proved by pathology at surgery. Four patients with a marked increase in Lac/Cr were diagnosed

as having brain abscesses, which was compatible with the histopathologic diagnoses. Unexpectedly, one patient with an increase in Lac/Cr was misdiagnosed as having a brain abscess but later diagnosed by histopathology as having gliosis (Figure 1). Changes in the ratios of the metabolites are compared with preoperative diagnosis and postoperative pathologic diagnosis in the Table. Case 1 had a metastatic brain tumor (Figure 2), Case 5 had post-radiation necrosis (Figure 3), and Case 8 had a brain abscess (Figure 4).

DISCUSSION

Previous proton MRS studies found that Cho signals in radiation necroses were lower than in recurrent brain tumors, leading to an increase in Lac/Cr and a decrease in Cho/Cr in patients with post-radiation necrosis [8,9]. We found a marked decrease in NAA/Cr, no change in Lac/Cr, and/or a slight increase in Cho/Cr in patients diagnosed with radiation necrosis. We also found a significant increase in Cho/Cr and a decrease in NAA/Cr in patients with metastatic brain tumors. In patients with cerebral abscesses, we found a marked increase in Lac/Cr.

We applied our hypotheses for radiation necrosis, tumor biology, and pathophysiology of cerebral abscesses to interpret these results.

The effects of radiotherapy that result in necrosis may have a latent period of a few months to a few years. Theories of the mechanism of the pathogenesis of radiation necrosis include vascular damage leading to chronic ischemia, demyelination as a result of glial cell injury [1], and cell

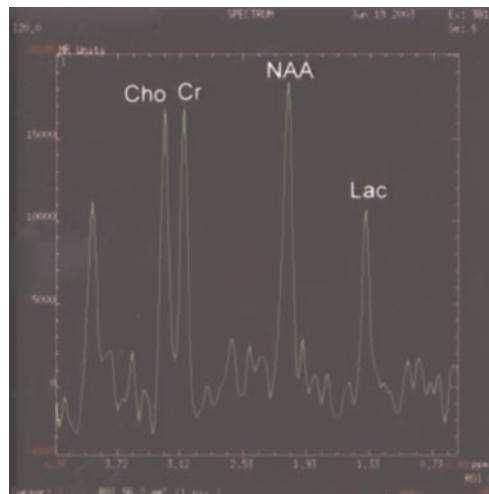
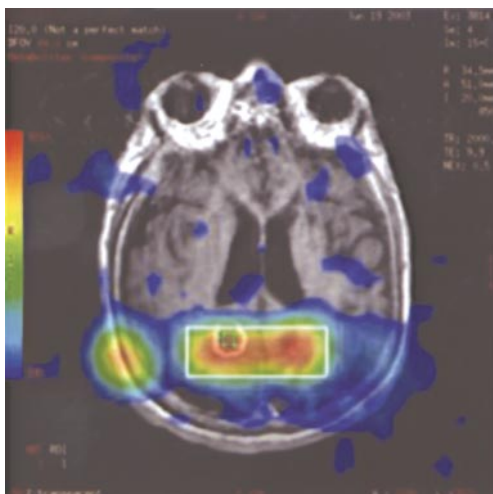


Figure 1. Case 12 was misdiagnosed as having a brain abscess, but actually had gliosis; magnetic resonance spectroscopy showed no change in NAA/Cr, an increase in Cho/Cr, and a decrease in Lac/Cr.

Table. Changes in the ratios of metabolites versus preoperative and pathologic diagnoses in 12 patients

Case	Age (yr)	Sex	NAA/Cr	Cho/Cr	Lac/Cr	Pre-op Dx by ¹ HMRS	Histopathologic Dx
1	68	M	↓	↑	↑	Metastatic brain tumor	Metastatic brain tumor (from lung Ca)
2	38	M	↓	↑	-	Metastatic brain tumor	Metastatic brain tumor (from NPC)
3	42	M	↓	↑	↓	Metastatic brain tumor	Metastatic brain tumor (from lung Ca)
4	66	M	↓	↑	-	Metastatic brain tumor	Metastatic brain tumor (from lung Ca)
5	49	M	↓	-	-	Radiation necrosis	Necrosis and fibrinous exudates
6	35	M	↓	-	-	Radiation necrosis	Necrosis and vascular wall
7	61	M	↓	-	-	Radiation necrosis	Necrotic brain tissue
8	52	F	-	↓	↑	Cerebral abscess	Cerebral abscess
9	63	M	↓	↓	↑	Cerebral abscess	Cerebral abscess
10	46	F	-	↓	↑	Cerebral abscess	Cerebral abscess
11	65	F	↑	↑	↑	Cerebral abscess	Cerebral abscess
12	85	M	-	↓	↑	Cerebral abscess	Gliosis

NAA = N-acetyl aspartate; Cr = creatine and phosphocreatine; Cho = choline-containing compounds; Lac = lactate; Pre-op = preoperative; Dx = diagnosis; ¹HMRS = proton magnetic resonance spectroscopy; ↓ = decrease; ↑ = increase; Ca = cancer; - = no change; NPC = nasopharyngeal carcinoma.

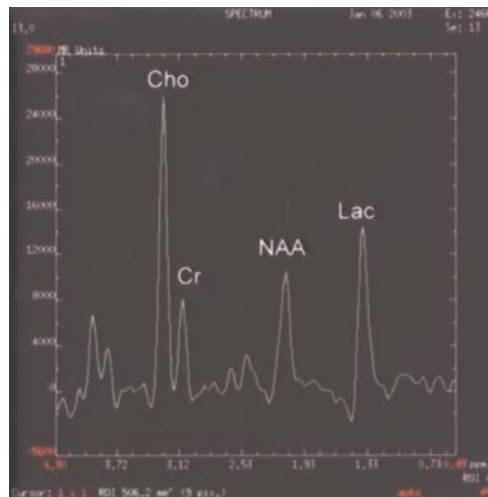
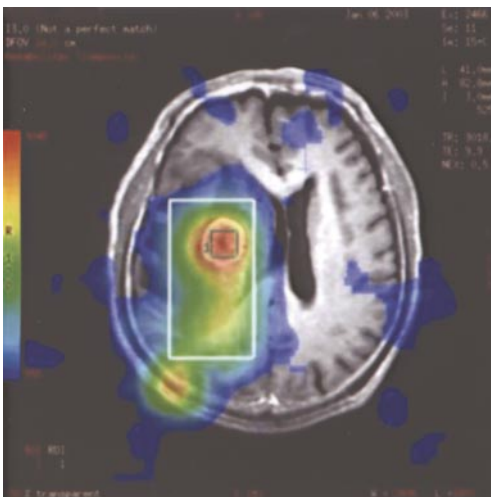


Figure 2. Case 1 had a metastatic brain tumor; magnetic resonance spectroscopy showed a decrease in NAA/Cr, and an increase in Cho/Cr.

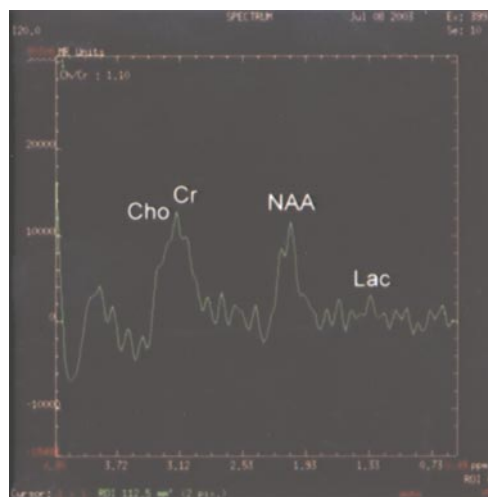
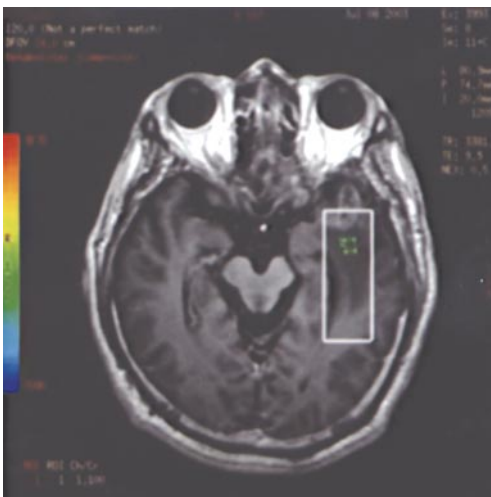


Figure 3. Case 5 had post-radiation necrosis; magnetic resonance spectroscopy showed a decrease in NAA/Cr, and no change in Cho/Cr.

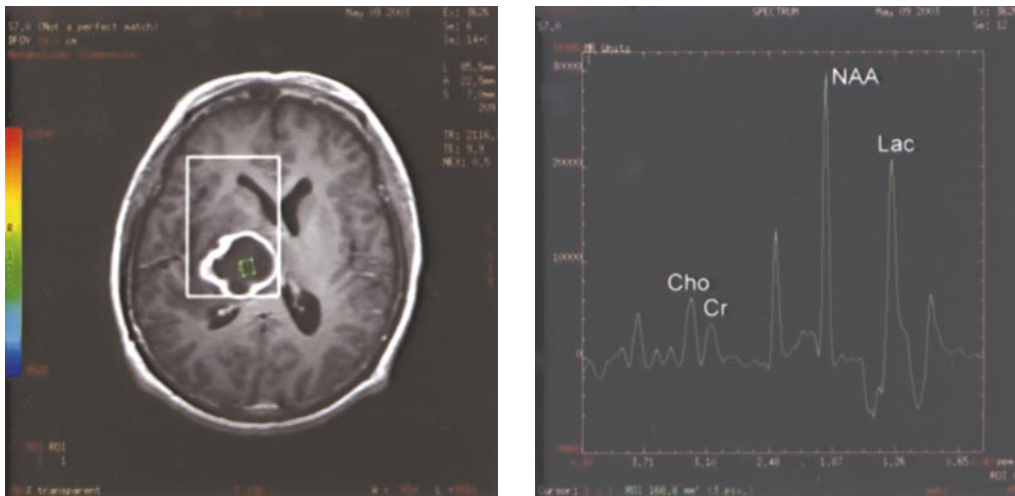


Figure 4. Case 8 had a brain abscess; magnetic resonance spectroscopy showed an increase in Lac/Cr.

membrane dysfunction due to lipid destruction by free radicals. NAA is found in neurons and thought to act as a marker [9]. A decreased NAA concentration results from a loss of neurons in multiple sclerosis [5,6], cerebral infarction, post-radiation necrosis, and brain tumors. All spectra must be considered for an accurate assessment. NAA alone is not a specific indicator for differential diagnosis. Cho signals are found in the cytoplasm and mainly relate to methyl groups from choline-containing compounds. An increased Cho concentration results from increased phospholipid turnover in tumor tissue and tumor activity. Lactate is the end product of anaerobic metabolism. Cerebral abscesses and cerebral infarction result in increased lactate production. Cr concentrations are relatively stable in brain lesions [8, 9]. Changes in the ratios of metabolites/Cr in proton MRS might reflect the concentrations of the metabolites.

CONCLUSIONS

We hypothesize that in metastatic brain tumor, a decrease in NAA/Cr combined with a marked increase in Cho/Cr reflects an increase in tumor activity and neuron cell loss. In post-radiation necrosis, a marked decrease in NAA/Cr combined with no change or a slight increase in Cho/Cr reflects necrotic change from chronic vascular damage and ischemia. If the patient has previously received radiotherapy, the probability of radiation necrosis should be examined. Lastly, in brain abscesses, a marked increase in Lac/Cr reflects anaerobic glycolysis by microorganisms.

We do not mislead readers into thinking that these lesions can be distinguished using proton MRS alone. History, presentation, physical examination, and neurologic

examination, together with all imaging studies, are fundamental to an exact diagnosis.

Although further investigation is necessary, the metabolic information provided by proton MRS combined with MRI is useful for differentiation among metastatic brain tumors, radiation necrosis, and brain abscess.

ACKNOWLEDGMENTS

We thank the Departments of Medical Imaging and Pathology, Kaohsiung Medical University Hospital, Kaohsiung, Taiwan.

REFERENCES

1. Kumar AJ, Leeds NE, Fuller GN, et al. Malignant gliomas: MR imaging spectrum of radiation therapy- and chemotherapy-induced necrosis of the brain after treatment. *Radiology* 2000; 217:377–84.
2. Stokkel M, Stevens H, Taphoorn M, et al. Differentiation between recurrent brain tumor and post-radiation necrosis: the value of 201Tl SPET versus 18F-FDG PET using a dual-headed coincidence camera – a pilot study. *Nucl Med Commun* 1999;20:411–7.
3. Thiel A, Pietrzyk U, Sturm V, et al. Enhanced accuracy in differential diagnosis of radiation necrosis by positron emission tomography-magnetic resonance imaging coregistration: technical case report. *Neurosurgery* 2000;46:232–4.
4. Thompson TP, Lunsford LD, Kondziolka D. Distinguishing recurrent tumor and radiation necrosis with positron emission tomography versus stereotactic biopsy. *Stereotact Funct Neurosurg* 1999;73:9–14.
5. Matthews PM, Francis G, Antel J, et al. Proton magnetic resonance spectroscopy for metabolic characterization of

- plaques in multiple sclerosis. *Neurology* 1991;41:1251-6.
6. Richards TL. Proton MR spectroscopy in multiple sclerosis: value in establishing diagnosis, monitoring progression, and evaluating therapy. *AJR Am J Roentgenol* 1991;157:1073-8.
 7. Szigety SC, Allen PS, Huyser-Wierenga D, et al. The effect of radiation on normal human CNS as detected by NMR spectroscopy. *Int J Radiat Oncol Biol Phys* 1993;25:695-701.
 8. Kuznetsov YE, Caramanos Z, Antel SB, et al. Proton magnetic resonance spectroscopic imaging can predict length of survival in patients with supratentorial gliomas. *Neurosurgery* 2003;53:565-74.
 9. Kamada K, Houkin K, Abe H, et al. Differentiation of cerebral radiation necrosis from tumor recurrence by proton magnetic spectroscopy. *Neurol Med Chir (Tokyo)* 1997;37:250-6.
 10. Preul MC, Caramanos Z, Villemure JG, et al. Using proton magnetic resonance spectroscopic imaging to predict in vivo the response of recurrent malignant gliomas to tamoxifen chemotherapy. *Neurosurgery* 2000;46:306-18.

利用核磁共振光譜分辨轉移性腦瘤、 放射後壞死及腦膿瘍

黃燕芬¹ 黃祖源² 黃旭霖¹ 關暉麗¹ 洪純隆¹

¹高雄醫學大學 附設醫院神經外科

²高雄市立聯合醫院外科

質子核磁共振光譜試以區分轉移性腦瘤、放射後壞死及腦膿瘍。十二個有病理證實的病灶，術前分析核磁共振掃描和質子核磁共振光譜。觀察病灶及周圍的四種主要代謝物的訊號強度：乙醯天門冬酸 (NAA)、膽鹼化合物 (Cho)、磷酸肌酸 (Cr)、及乳酸 (Lac)。轉移性腦瘤呈現 NAA/Cr 下降與 Cho/Cr 上升，放射後壞死呈現 NAA/Cr 下降與 Cho/Cr 不變，腦膿瘍呈現 Lac/Cr 上升。高 Cho 意指腫瘤生長轉化的結果，Lac 則為微生物無氧代謝的結果。初步結論是核磁共振光譜有助於區分轉移性腦瘤、放射後壞死及腦膿瘍。

關鍵詞：核磁共振掃描，質子核磁共振光譜，轉移性腦瘤，放射後壞死，腦膿瘍
(高雄醫誌 2004;20:437-42)

收文日期：93 年 4 月 23 日

接受刊載：93 年 5 月 28 日

通訊作者：洪純隆醫師

高雄醫學大學附設醫院神經外科

高市自由一路 100 號