

# PRELIMINARY EXPERIENCE WITH ANTERIOR INTERBODY TITANIUM CAGE FUSION FOR TREATMENT OF CERVICAL DISC DISEASE

Chung-Nan Lin, Yu-Chuan Wu, Nai-Phon Wang,<sup>1</sup> and Shen-Long Hwang<sup>2</sup>  
Departments of Neurosurgery and <sup>1</sup>Orthopedics, Kuang-Tien General Hospital, Dajia, Taichung; <sup>2</sup>Department of Neurosurgery, Kaohsiung Medical University, Kaohsiung, Taiwan.

This study evaluated the efficacy and safety of titanium cage implants in cervical reconstruction to treat cervical spondylosis. Surgical data covered a 4-year period from January 1999 to December 2002 and included 34 consecutive patients, 20 men and 14 women, with ages ranging from 27 to 84 years (mean, 57 years). Patients underwent anterior cervical microdiscectomy followed by interbody fusion with a titanium cage implant (rather than an autogenous iliac crest bone graft) at a single level ranging from C3 to C7. Twenty-one patients had a herniated intervertebral disc, nine had degenerative disc disease, and four had previous failed autograft fusion surgery that required revision. At clinical presentation, 26 patients had neck pain, 23 had radiculopathy, and nine had myelopathy. Diagnostic imaging studies included spinal dynamic roentgenography, computerized tomography, and magnetic resonance imaging. Lesions were located at C3–4 in seven cases, C4–5 in 14 cases, C5–6 in nine cases, and C6–7 in four cases. The follow-up period ranged from 7 to 48 months (mean, 26 months). Results revealed that the procedure was technically feasible. There were no intra- or postoperative complications. The most commonly used cage was 9 mm high. Imaging studies showed no cage instability, migration, or pseudarthrosis. Although mild subsidence (< 5 mm) was observed in three cases, these patients preserved adequate postoperative cervical lordosis and the subsidence did not preclude a good clinical result. The advantages of this procedure over a similar operation using traditional tricorticate bone graft are: no graft morbidity; shorter operation time (mean time saved, 35 minutes); reduced blood loss (average blood loss, 75 mL); and early postoperative ambulation (mean, 4.7 hospital days). Nearly all patients rapidly lost their neck pain (92%, 24/26) and radicular symptoms (87%, 20/23) after surgery. The recovery rate from myelopathy was 44% (4/9). Progressive bony shield formation over the anterior/posterior cortex (sentinel sign) indicated fusion in five cases.

**Key Words:** titanium cage, anterior fusion, cervical disc disease  
(*Kaohsiung J Med Sci* 2003;19:208–16)

Cervical spondylosis (degenerative changes in the cervical spine resulting in neck pain, radiculopathy

and/or myelopathy) is a commonly encountered condition in neurosurgical practice. Its causes include alteration in normal disc anatomy, both degenerative disc disease (DDD) and herniated intervertebral disc (HIVD), for which anterior discectomy is mandatory. Anterior discectomy without fusion, however, causes a disturbance in the anatomic relationships of the cervical spine and has been related to postoperative

Received: January 15, 2003      Accepted: March 21, 2003  
Address correspondence and reprint requests to: Dr. Chung-Nan Lin, Department of Neurosurgery, Kuang-Tien General Hospital, 321 Jing Gwo Road, Dajia, Taichung Hsien, Taiwan.  
E-mail: johnchungnan@yahoo.com.tw

neuralgia, foraminal stenosis, and kyphosis [1–3]. In Dennis et al's series, all cases lost disc height after surgery [4]. Therefore, anterior decompression and stabilization through interbody fusion has become a widely accepted surgical procedure. Tricorticate iliac crest autograft is the gold standard for bone fusion but is associated with morbidity at the bone graft donor site [5,6]. Whitecloud et al found that autogenous bone graft was associated with 20% of donor site morbidities [7]. Problems such as pseudarthrosis, graft collapse, and extrusion over the recipient site also persist with the accepted method of harvesting and implanting bone autografts [8]. Stauffer and Coventry had a 43% pseudarthrosis rate in their 83-case series [9].

Since biomechanical studies suggest that stabilization is most efficient in the anterior column where most (80%) spine force acts, these considerations led to the development of interbody fusion cages that can fill the defect space and contribute to long-term stability by underlying osteoincorporation but with almost no donor and recipient site complications [10].

The original idea of a cage came from Bagby, who, in an effort to treat cervical instability in horses, invented the bone basket and coined the term distraction-compression stabilization to describe the technique of annular distraction leading to cage impaction in the intervertebral space [11]. In vitro testing of the interbody titanium cage indicated improved biomechanics compared to conventional grafting mainly in flexion-extension and torsion. Histologic and radiologic studies in animals showed good fusion [11,12]. Wigfield and Nelson compared the use of autograft, allograft, and cage fusion techniques and found that the failure rates were 15%, 21%, and 0%, respectively [13]. Many reports have described the advantages of, and successful fusion rates with, cage implants in the treatment of lumbar and cervical spondylosis [10,13–15].

The purpose of this outcome assessment study was to review the early results obtained in managing a variety of degenerative cervical disorders using anterior cervical microdiscectomy and interbody stability with cage fusion. We assessed the clinical and radiologic results to evaluate the ability of cage fusion to stabilize the cervical spine without use of iliac crest bone grafts, thus avoiding complications at both donor and recipient sites.

## MATERIALS AND METHODS

From January 1999 to December 2002, 34 patients with degenerative cervical disc disorder, 20 men and 14 women, aged between 27 and 84 years (mean, 57 years) were enrolled in the study. All were treated using decompressive microdiscectomy followed by placement of a titanium cage packed with cancellous bone (harvested from the anterior vertebral spur) to reconstruct the anterior column. Inclusion criteria were single-level degenerative cervical disc disease between C3 and C7 with neck pain and/or radiculomyelopathy. These lesions required anterior decompression and subsequent fusion. Among the 34 cases, HIVD accounted for 21 and DDD for nine. The other four patients had pseudarthrosis due to failure of a previous attempted autograft anterior cervical interbody fusion (ACIF) and recurrent symptoms necessitating revision. Two cases were concomitantly accompanied by Grade I (< 3 mm) spondylolisthesis or retrolisthesis. Twenty-six patients had significant neck pain, 23 had symptoms of radiculopathy (arm/shoulder pain, numbness, soreness), and nine had myelopathy (motor deficit – paresis) or suffering, spastic gait. The duration of symptoms ranged from 4 to 23 months (mean, 12 months). All patients underwent preoperative plain anteroposterior and lateral cervical spine dynamic roentgenography in flexion and extension. Nerve conduction velocity test and electromyography were performed if necessary to rule out other possibilities. Magnetic resonance imaging (MRI) and computerized tomography were carried out routinely to confirm a mechanical cause of the clinical diagnosis.

The cage prosthesis used in this study, the Vigor Disc Spacer (Central Medical Technologies Inc., Oakland, CA, USA), is a rectangular block of biocompatible titanium alloy with holes and grooves cut into it. Its anterior height varies between 7 and 10 mm. Both upper and lower zigzagged surfaces match the vertebrae safely, provide immediate strong support, and allow fibrous union and bony growth to occur.

The operative technique used in this study was similar to the traditional ACIF procedure. All patients underwent surgery via a right anterior cervical approach. After right-sided collar incision, complete discectomy was performed down to the posterior longitudinal ligament. The disc space was thoroughly cleaned so that no intervening tissue lay between the

body fusion beds. The cartilaginous end plate was completely excised to maintain structural integrity and to discourage subsidence. A suitable-sized cage was then inserted under distraction-insertion-compression to restore the annular tension and to keep the anterior column in physiologic lordosis. Cage insertion was facilitated by use of a laminar spreader or a Casper pin retractor for distraction. The cancellous bone graft harvested from the anterior vertebral spur was also packed into the cage cavity for maximum contact with both the upper and lower end plate. The cage was structurally wedged. Its anterior location was 2 mm below the anterior cortex of the vertebral body.

Postoperative evaluation of symptomatic improvement was based on the criteria of Odem et al [16]. Average operative time, blood loss, hospitalization days, and the possibility of overall complications were recorded. Follow-up plain roentgenography was performed routinely on the first postoperative day. Periodic lateral flexion and extension roentgenographs to judge fusion were undertaken and further neurologic examinations were performed at outpatient appointments about 4 weeks and approximately 3, 6, and 12 months after surgery. Successful interbody fusion was defined as a flexion-extension range of motion at the fusion site of less than 5°, preserved disc height with no collapse-induced kyphosis, and progressive trabecular bridge formation at the anterior and/or posterior cortex of the involved vertebrae [17].

## RESULTS

The procedure was technically feasible and the results were encouraging. The cages were located at C3–4 in seven patients, C4–5 in 14 patients, C5–6 in nine patients, and C6–7 in four patients (Figure 1). The most common cage prosthesis used in this study had a width of 12 mm, a depth of 12 mm, and a height of 9 mm. Estimated blood loss ranged from 35 mL to 125 mL, with an average of 75 mL. Hospital stay was minimal, ranging from 2 to 7 days with an average of 4.7 days. Since no iliac bone harvesting was required, we found that we could save one-fourth of surgical time (average, 35 minutes) compared to the traditional autograft procedure. There were no intraoperative or postoperative complications related to the prosthetic cage, and no dislodgement or failure. Two patients had transient postoperative complica-

tions (one with swallowing difficulty and another with mild hoarseness), but roentgenographs showed that the cages were in a good position. Both symptoms resolved by 1 month after surgery.

Postoperative follow-up varied from 7 to 48 months (mean, 26 months). Satisfactory results for neck and radicular pain were achieved by the first postoperative day and deficits had almost cleared by 3 months. Most patients (92%, 24/26) lost their neck pain, and most of those presenting with radiculopathy (87%, 20/23) showed dramatic improvement by the first day after surgery. Patients with myelopathy, however, demonstrated more varied recovery from motor deficits: only four of the nine patients (44%) showed good recovery, four achieved a little improvement, and one had no improvement even after additional posterior decompressive laminectomy. The four patients who underwent revision of previous traditional ACIF failure (collapse, expulsion, and pseudarthrosis of bony graft) responded well to the technique, demonstrating satisfactory symptomatic relief and normal radiologic contour.

There was roentgenographic evidence of ideal cage position in all patients. The graft appeared to be extremely stable after surgery on flexion and extension views. No visible motion (> 5°) was seen and proper lordosis was maintained after surgery. There was minimal cage subsidence into the adjacent vertebral bodies (< 5 mm) in three cases, but this did not preclude a good clinical outcome and preservation of cervical lordosis. Progressive formation of a bony shield outside the cage (the sentinel sign) was observed in five patients on roentgenographs at 6 or 12 months after surgery, which indicated fusion (Figure 2).

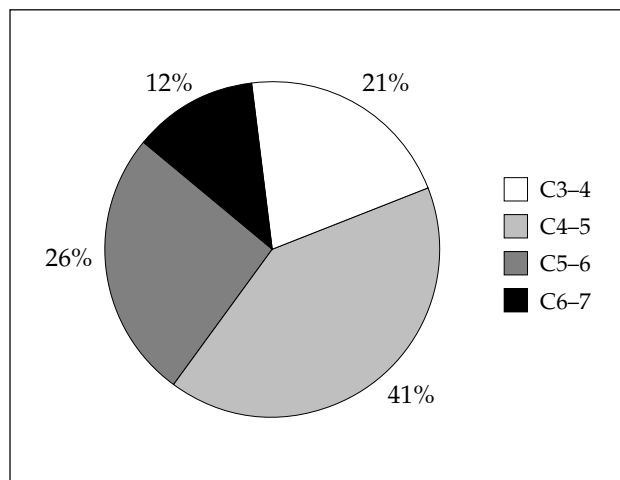
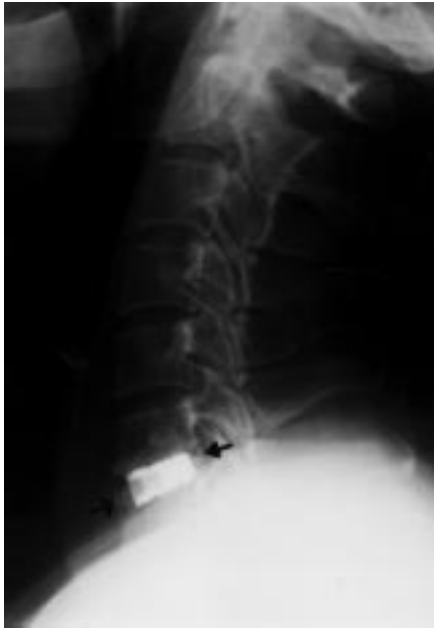

Figure 1. Distribution of cervical spine lesions.



**Figure 2.** Lateral roentgenograph of cervical cage fusion 6 months after surgery demonstrates progress with remodeled bridging bone anterior/posterior to the device.

### Illustrative cases

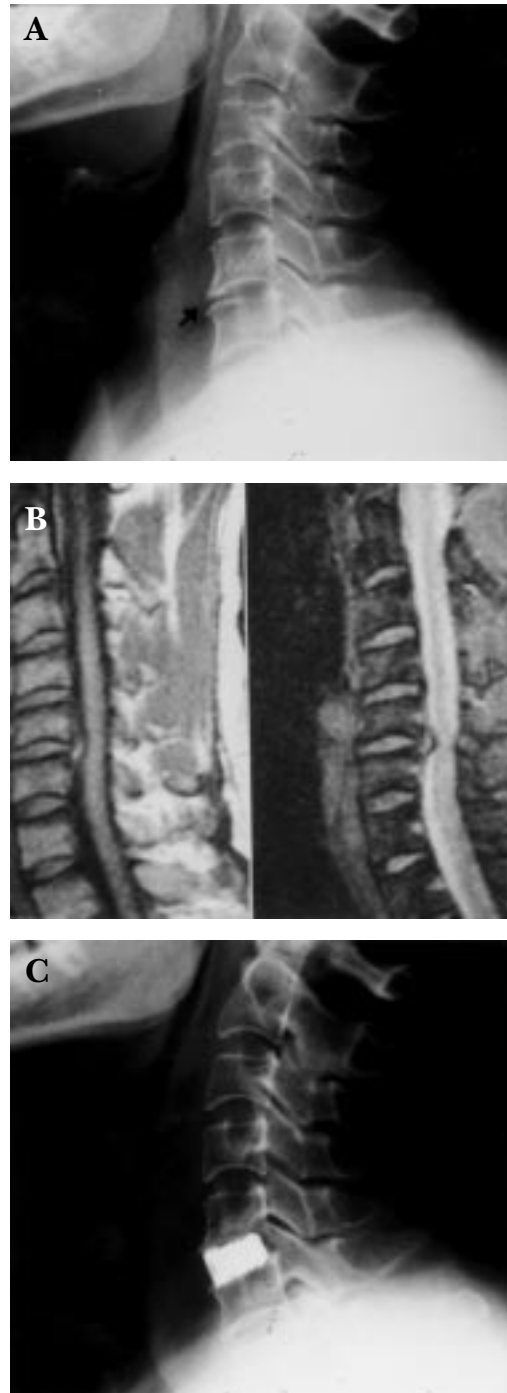#### Case 1

A 19-year-old male was admitted with severe neck pain radiating to the right arm for 7 months. Cervical roentgenography and MRI showed that he had C5–6 spondylosis with disc protrusion to the right side, which was causing spinal canal stenosis (Figures 3A and B). After anterior cervical discectomy, a 9 mm cage implant was grafted. When the patient awoke, the arm and neck pain had gone. Roentgenography at follow-up 6 months later showed good cervical lordosis and alignment (Figure 3C).

#### Case 2

In March 1999, a 41-year-old man underwent a Smith-Robinson procedure with iliac crest autograft due to C5–6 HIVD. The postoperative course was uneventful. After 8 weeks, he complained of recurrent neck pain. Bilateral arms were also involved at 5 months, and the pain was more severe on the right side. Follow-up roentgenography demonstrated a failed graft expulsion, collapse, and pseudarthrosis (Figure 4A). All conservative treatments were tried, including narcotic medication, rehabilitation therapy, and cervical collar, but they were not effective. The patient agreed

to repeat surgery on August 24, 1999. After drilling out the degenerate graft, the distracted intervertebral space was grafted with a 9 mm cage, allowing widening of the foramina and correction of kyphosis. No



**Figure 3.** (A) Cervical spinal roentgenography and (B) magnetic resonance imaging reveal C5–6 herniated intervertebral disc. (C) Postoperative follow-up roentgenography at 6 months shows good alignment.

further postoperative complaints were noted. Roentgenography showed good alignment 4 months later (Figure 4B).

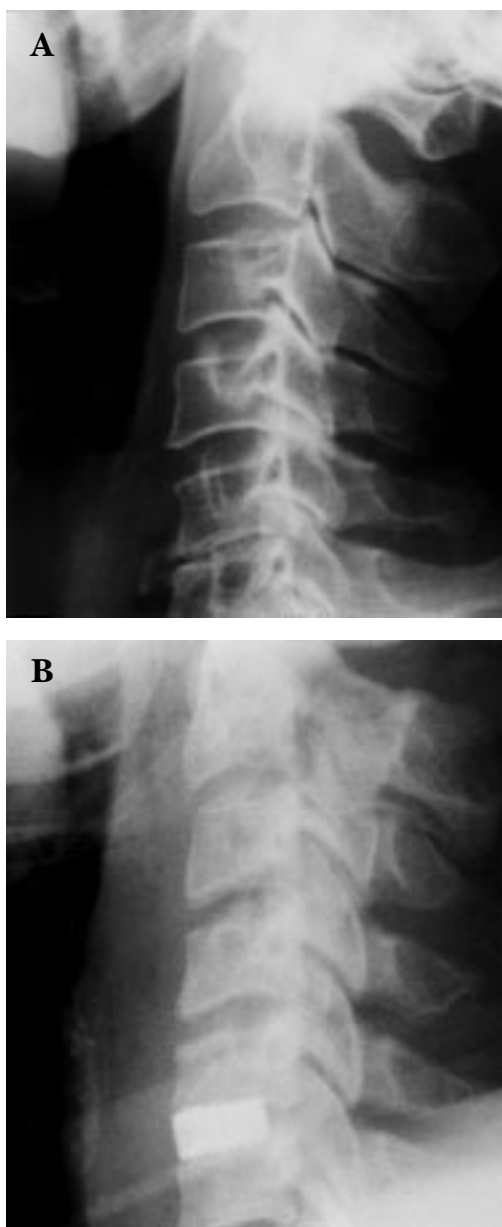
## DISCUSSION

In DDD or following surgical discectomy for HIVD, segmental stenosis may occur. A combination of disc

herniation, posterior osteophyte formation, overriding facets, and hypertrophy and infolding of the ligamentum flavum may contribute to compression of the nerve root as it goes through the intervertebral foramen, resulting in recurrence of radiculopathy and myelopathy. Maintenance of disc height and neuroforamen width and restoration of normal lordosis through interbody fusion helps to restore normal anatomy. Anterior cervical fusion was first reported in 1958 when Smith and Robinson [18] and Cloward [19] reported using a bone graft for fusion. Indicative ACIFs using Cloward or Smith-Robinson procedures yielded good results over nearly 40 years. However, it is well recognized that much postoperative morbidity is related to both donor and recipient sites [18,19]. Negative side effects such as graft collapse, expulsion, pseudarthrosis, and graft site morbidities have been reported [20].

In 1960, Bailey and Badgley presented their technique using an inlay graft for fusion [21]. Ray [17] and Kuslich et al [22], in association with Bagby, who had done earlier work on horses [11], developed threaded titanium fusion cages. Because the rigidity of the cage allowed disc space preservation and the cages were easy to use, metallic cages housing cancellous bone have become increasingly popular for interbody fusion. Many preliminary studies reported successful results and the advantages of using threaded titanium cages in the treatment of degenerative spinal disorders [10, 20,23]. Laboratory tests on individual and stocked cage prostheses in the calf spine have also shown that the cages are mechanically superior to reconstruction or using blocks of bone or methylmethacrylate [24]. From these studies and our early successful results, we believe that cages will gain wide acceptance for management of degenerative diseases of the cervical spine.

Recently, the concept of a degenerative disc as a pain generator has gradually been accepted [25–27]. Therefore, interbody cage insertion following discectomy for DDD or HIVD to maintain sufficient disc height and neuroforamen volume to support the anterior column has become an indicative and mandatory step [15]. The indications for cage implantation in this study included: cervical DDD and/or HIVD with discogenic neck pain, arm/shoulder radiating pain, or myelopathy confirmed by history and roentgenographic study; up to Grade I spondylolisthesis or retrolisthesis at the involved vertebrae; involvement of discs between C3 and C7 or T1 and one or two



**Figure 4.** (A) Pseudarthrosis and kyphosis with graft collapse 2 months after a Smith-Robinson procedure with autograft. (B) Successful re-expansion of the disc space using interbody titanium cage fusion.

contiguous levels; and pseudarthrosis from previous failed fusion attempt. We do not recommend that the device be implanted in an active infection site. Also, the safety and effectiveness of the cage in patients with spondylolisthesis or retrolisthesis of Grade II or greater (> 5 mm), systemic or terminal illness (malignancy), and significant loss of quantity or quality of vertebral bone stock (severe osteoporosis) have not yet been established. Although multilevel ( $\geq 2$  levels) involvement has been reported in other series, we only used a single-level procedure in this study. Contraindications in other reports, such as post-traumatic instability and malignant spinal tumor, have changed. Lin et al [28] and Mizuno and Nakagawa [29] reported using cage fusion to treat traumatic cervical spine fractures, and other authors have tried both cage and anterior cervical plate and screw (ACPS) fixation to manage spinal malignancy [30].

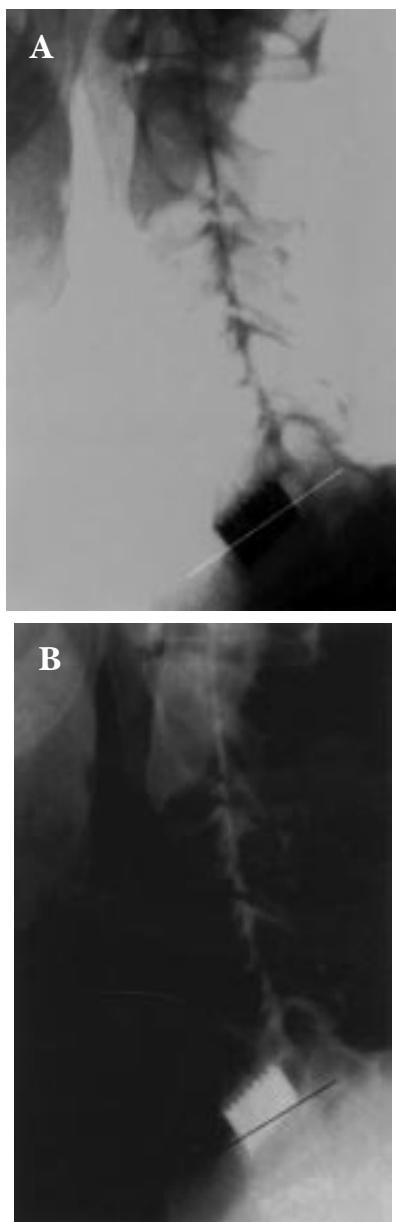
The basic concept of the cage is to maintain the tension forces of annular fibrosis through a distraction-compression mechanism and so avoid possible collapse of the autograft during the resorption phase, which may lead to pseudarthrosis [11,31]. The special titanium-alloy instruments used in this study are biocompatible, available in various sizes (7–10 mm in diameter), and provided with a bone-collecting reamer. The hollow inner space allows insertion of a cancellous bone graft to assist bone fusion. The outer cage provides support and has tooth-like serrations that resist expulsion or retropulsion of the prosthesis when placed into the intervertebral space. With the cancellous bone graft in intimate contact with living spongy cells on either side of the cage, osteogenesis and bone fusion are enhanced by bleeding vertebral bone and further stabilization is enhanced by threads firmly screwed into both end plates [11]. Since the device is autostabilized and does not slip, further immobilization by an ACPS or external collar fixation is not indicated [8,32–34]. This structure therefore has several advantages: it corrects biomechanical kyphotic deformity and maintains anatomic lordosis and sagittal balance; it prevents further facet joint dislocation and widens the neuroforamen; it offers immediate stability and stiffness for loading-stress balance; it provides a proper environment for arthrodesis; it limits morbidity and operative complications; and it needs no auxiliary ACPS fixation.

The cage fusion technique is quite similar to classic ACIF. Slight neck extension is essential to restore postoperative lordosis. The appropriate cage size can be

selected with a template during surgery. Emphasis is on intervertebral distraction to allow good cage impaction and prevent further subsidence due to over-distraction.

Our preliminary results were satisfactory both clinically and radiologically. Neck pain (92%) and radicular pain (87%) resolved quickly. Motor deficits improved more slowly during hospitalization and follow-up. Cage fusion was achieved in all cases. From a large surgical series of 357 DDD cases, Matge and Leclercq reported postoperative improvement of radiculopathy (95%) and myelopathy (50%) [10]. Since no iliac bone harvesting procedure was needed, our procedure saved an average of 35 minutes of operative time and kept blood loss as low as 35 mL. Also, there were almost no complaints of postoperative wound pain or discomfort from most patients. Hospital stay was short; most patients (82%, 28/34) were discharged within 5 days after surgery. In Majd et al's series, 95% of patients left hospital within 48 hours [6]. They were able to return to work with almost complete relief of neck pain and radiculopathy and improved motor deficit.

The possible operative adverse effects following cage surgery include dural leakage and nerve damage after surgical trauma, discomfort due to the presence of the device, mental sensitivity or allergic reaction, bending or fracture of the implant, delayed union or nonunion, and decrease in bone density due to stress shielding. None of these were observed in our patients. Over-sized interbody fusion cages can sometimes cause complications of serious subsidence and collapse of intervertebral space. Only three cases in our study showed postoperative subsidence, which was minimal, on follow-up roentgenography at 6 or 12 months (Figure 5). There were no complications such as cage dislodgement, kyphotic deformity, or nonunion with instability. To prevent such complications, the selection of a suitable cage size is strongly recommended; its area of contact with the adjacent vertebrae should be large enough to resist excessive subsidence and small enough to prevent stress protection of the tissue growing in the cage. Also, the patient should avoid frequent violent neck movements [35]. Body fusion was established when there was no instability on lateral dynamic roentgenographs (< 5° in flexion-extension) at 6 months postoperatively. If there was no fusion at 6 months, the examination was repeated at 12 months [20]. Using these criteria, Matge showed that 90% of patients at 6 months and 100% at 12 months had fusion [20]. Fusion was noted in all patients in our study.



**Figure 5.** Mild anterior cage subsidence.

The sentinel sign was found in five cases.

One report compared the results of the cage plus cancellous bone graft to autograft and to decorticate only, and found that the distraction and stability of the cage plus cancellous bone graft was best, even better than autograft plus transpedicular plate and screw; decortication only had the poorest result [36]. Since there was no failure of the cage fusion procedure in our study or in Wigfield and Nelson's study [13], cage fusion may be considered superior to traditional procedures in cervical reconstruction. In summary, treating cervical

spondylosis with titanium cage fusion is a safe and easy procedure. Immediate stability with good clinical response and no graft morbidity or complications are the main advantages of this implant.

## REFERENCES

1. Martins AN. Anterior cervical discectomy with and without interbody graft. *J Neurosurg* 1976;44:290–5.
2. Benini A, Krayenbuhl H, Bruder R. Anterior cervical discectomy without fusion: microsurgical technique. *Acta Neurochir (Wien)* 1982;61:105–10.
3. Wilson D, Campbell D. Anterior cervical discectomy without bone graft. *J Neurosurg* 1977;47:551–5.
4. Dennis S, Watkins R, Landaker S, et al. Compression of disc space heights after anterior lumbar interbody fusion. *Spine* 1989;14:876–8.
5. White AA, Southwick WO, Dupont R, et al. Relief of pain by anterior cervical spinal fusion for spondylosis. *J Bone Joint Surg Am* 1973;55:525–34.
6. Majd ME, Vadhva M, Holt RT. Anterior cervical reconstruction using titanium cages with anterior plating. *Spine* 1999;24:1604–10.
7. Whitecloud TS, Ricciardi JE, Werner JG. Bone graft, hardware, and halo fixator related problems. In: Clarke CR, ed. *The Cervical Spine*, 3<sup>rd</sup> ed. Philadelphia: Lippincott-Raven, 1998: 903–15.
8. Connolly PJ, Esses SI, Kostuik JP. Anterior cervical fusion: outcome analysis of patients fused with and without anterior cervical plates. *J Spinal Disord* 1996;9:202–6.
9. Stauffer RN, Coventry MB. Anterior interbody lumbar fusion. Analysis of Mayo Clinic series. *J Bone Joint Surg Am* 1972;54A: 756–68.
10. Matge G, Leclercq TA. Rationale for interbody fusion with threaded titanium cages at cervical and lumbar levels. Results on 357 cases. *Acta Neurochir (Wien)* 2000;142:425–34.
11. Bagby GW. Arthrodesis by the distraction-compression method using a stainless steel implant. *Orthopedics* 1988;11: 931–44.
12. De Bowes RM, Grant BD, Bagby GW, Butts MK. Cervical vertebral interbody fusion in the horse: a comparative study of bovine xenografts and autografts supported by stainless steel baskets. *Am J Vet Res* 1984;45:191–9.
13. Wigfield CC, Nelson RJ. Nonautologous interbody fusion materials in cervical spine surgery: how strong is the evidence to justify their use? *Spine* 2001;26:687–94.
14. McAfee PC. Interbody fusion cage in reconstruction operation on the spine. *J Bone Joint Surg Am* 1999;81A:859–81.
15. Lin CN, Wu YC, Wang NP. Interbody fusion cage. *Taiwan Med J* 2002;45:256–61.
16. Odem GL, Finney W, Woodhall B. Cervical disk lesions. *JAMA* 1958;16:23–8.
17. Ray CD. Threaded titanium cages for lumbar interbody fusions. *Spine* 1987;22:667–80.
18. Smith GW, Robinson RA. Treatment of certain cervical spine

- disorders by anterior removal of the intervertebral disc and interbody fusion. *J Bone Joint Surg Am* 1958;40:607-23.
19. Cloward RB. The anterior approach for removal of ruptured cervical discs. *J Neurosurg* 1958;15:602-17.
  20. Matge G. Anterior interbody fusion with BAK-cage in cervical spondylosis. *Acta Neurochir (Wien)* 1998;140:1-8.
  21. Bailey RW, Badgley CE. Stabilization of cervical spine by anterior fusion. *J Bone Joint Surg Am* 1960;42:565-94.
  22. Kuslich SD, Oxland TR, Jansen RC, Ulstrom CL. *The BAK Interbody Fusion System. Early Clinical Results of Treatment for Chronic Low Back Pain*. San Diego, CA: North American Spine Society, 1993.
  23. Eck KR, Bridwell KH, Ungacta FF, et al. Analysis of titanium mesh cages in adults with minimum two-year follow-up. *Spine* 2000;25:2407-15.
  24. Shono Y, McAfee PC, Cunningham BW, Brantigan JW. A biomechanical analysis of decompression and reconstruction methods in the cervical spine. Emphasis on a carbon-fiber-composite cage. *J Bone Joint Surg Am* 1993;75:1674-84.
  25. Kuslich SD, Ulstrom C, Michael CJ. The tissue origin of low back pain and sciatica: a report of pain response to tissue stimulation during operations on the lumbar spine using local anesthesia. *Orthop Clin North Am* 1991;22:181-7.
  26. Olmarker K, Blomquist J, Stromberg J, et al. Inflammatory properties of nucleus pulposus. *Spine* 1995;20:665-9.
  27. Schwarzer AC, Aprill CN, Derby R, et al. The prevalence and clinical features of internal disc disruption in patients with chronic low back pain. *Spine* 1995;20:1878-83.
  28. Lin CN, Wu YC, Wang NP. Titanium cage fusion for reconstruction of unstable anterior cervical fractures. *Formosa J Surg* 2002;35:173-81.
  29. Mizuno J, Nakagawa H. Threaded fusion cage for lumbar spondylolisthesis. *Neurol Med Chir (Tokyo)* 1998;38:155-60.
  30. Vahldiek MJ, Panjabi MM. Stability potential of spinal instrumentations in tumor vertebral body replacement surgery. *Spine* 1998;23:543-50.
  31. Weiner BK, Fraser RD. Spine update lumbar interbody cages. *Spine* 1998;23:634-40.
  32. Eck KR, Lenk LG, Bridwell KH, et al. Radiographic assessment of anterior titanium mesh cages. *J Spinal Disord* 2000;13:501-10.
  33. Butts MK, Kuslich SD, Bechold JE. *Biomechanical Analysis of a New Method for Spinal Interbody Fixation*. Boston, MA: American Society of Mechanical Engineers, 1987.
  34. Chen D. Increasing neuroforaminal volume by anterior interbody distraction in degenerative lumbar spine. *Spine* 1995;20:74-9.
  35. Watters WC, Levinthal R. Anterior cervical discectomy with and without fusion. *Spine* 1994;19:2343-7.
  36. Sandhu HS, Turner S, Kabo JM, et al. Distractive properties of a thread interbody fusion device. *Spine* 1996;21:1202-10.