

RARE ANATOMIC ENTITY OF QUADRICUSPID AORTIC VALVE WITH AORTIC INSUFFICIENCY: A CASE REPORT

Po-Chih Chang,¹ Ching-Cheng Lin,^{2,3} Chee-Siong Lee,^{2,3} Pao-Hui Wang,¹ and Ying-Fu Chen^{1,3}
¹Division of Cardiovascular Surgery, Department of Surgery, and ²Division of Cardiology, Department of Internal Medicine, Kaohsiung Medical University Hospital, and
³Faculty of Medicine, College of Medicine, Kaohsiung Medical University, Kaohsiung, Taiwan.

Quadricuspid aortic valve (QAV) is a rare congenital heart defect that often causes symptomatic aortic insufficiency in adulthood, imposing valve replacement. Herein, we describe one unusual case of QAV which underwent valve replacement uneventfully.

Key Words: aortic insufficiency, quadricuspid aortic valve
(*Kaohsiung J Med Sci* 2007;23:422–5)

The most common congenital abnormality of the aortic valve is bicuspid aortic valve, with an estimated incidence of about 2% of the general population [1]. Of note, anatomically isolated congenital valvular aortic insufficiency commonly occurs with bicuspid aortic valves, uncommonly with congenitally malformed trileaflet aortic valves (cuspal inequality) or unicommissural valves, and rarely with isolated quadricuspid aortic valves (QAVs). We report one patient who had QAV with aortic insufficiency, who presented with exertional dyspnea, and to and fro heart murmurs for 1 year.

CASE PRESENTATION

A 65-year-old male patient, who had a past history of chronic obstructive pulmonary disease, presented

with dyspnea on exertion for a year. On physical examination, a 3/6, to and fro diastolic murmur over the left sternal border and expiratory wheezing were audible. Chest roentgenography showed cardiomegaly. Transthoracic echocardiography disclosed severe aortic insufficiency without valve sclerosis. Meanwhile, left ventricular end diastolic and systolic dimensions were determined to be 63.3 mm and 39.2 mm. Aortic root angiography demonstrated four aortic valve cusps with nearly equal size and aortic insufficiency jet (Figure 1). No other abnormality was documented at this time.

Thereafter, he underwent elective aortic valve replacement with 21 mm St. Jude Medical mechanical valve (St. Jude Medical, Inc., St. Paul, MN, USA) without incident. During surgical exploration, thin and morphologically symmetrical cusps with four commissures were confirmed (type A, according to the classification of Hurwitz and Roberts) (Figure 2) [2]. On histologic examination, the resected cusps showed fibrotic thickening with slight calcification and no sign of previous inflammatory disease. The patient underwent follow-up 8 months later and the postoperative echocardiography showed improved left ventricular end diastolic and systolic dimensions of 42.0 mm and 25.5 mm.

Received: January 19, 2007 Accepted: February 26, 2007
Address correspondence and reprint requests to: Dr Ying-Fu Chen, Division of Cardiovascular Surgery, Department of Surgery, Kaohsiung Medical University Hospital, 100 Tzyou 1st Road, Kaohsiung 807, Taiwan.
E-mail: yfchen@cc.kmu.edu.tw

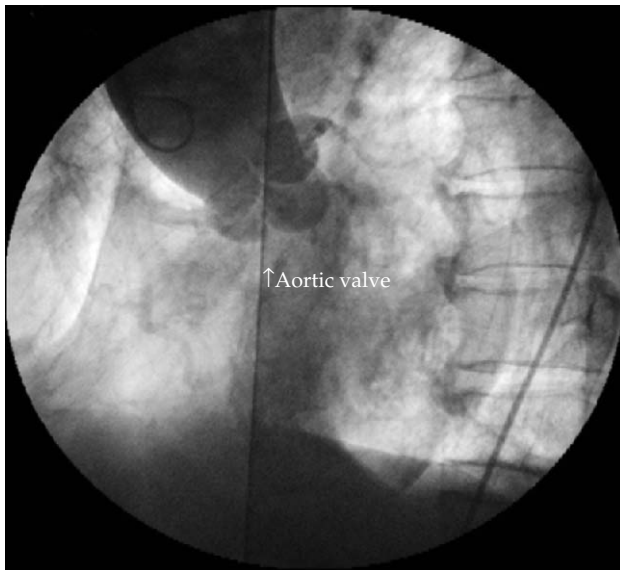


Figure 1. Aortogram shows "four-equal cusp" aortic valve with insufficient jet.

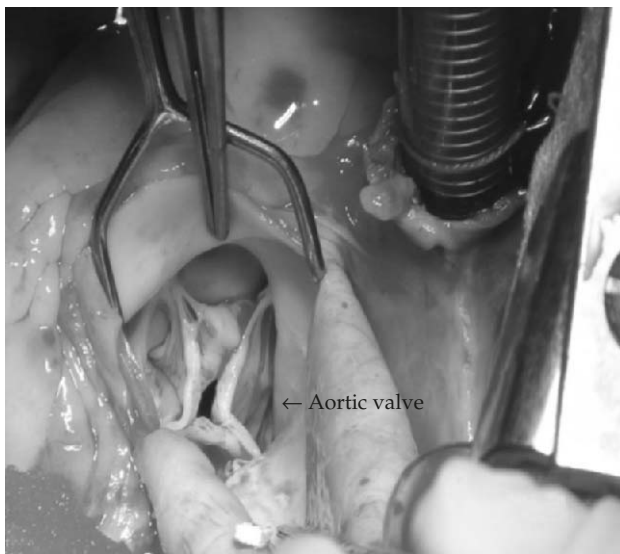

Figure 2. Perioperative view of the aortic valve with four equivalent leaflets.

DISCUSSION

The first case report of QAV, carrying the predicted incidence of 0.008%, was published by Balington in 1862 [3,4]. Moreover, it has been estimated to have an incidence of about 1% among patients with pure aortic insufficiency [5]. The incidence of QAV was about 1.3% (2/140) among the surgically treated patients with pure aortic insufficiency at our institution, which is similar to the reported data. At present, it is estimated

that more than 200 cases of QAV have been reported [6]. In reviewing the available data on QAV, most of them were discovered after the age of 40 (81%, 127/157 patients). This means that QAV could permit larger numbers of patients with this disorder to reach post-adolescence or even adulthood.

For the pathogenesis of QAV, several mechanisms have been proposed, such as excavation of one of the valve cushions or septation of a normal valve cushion from inflammatory process [7,8]. Nevertheless, the definite pathophysiology of QAV causing aortic insufficiency remains controversial. The anatomical anomaly of the cusps might induce unequal shear forces, which give rise to malcoaptation of the leaflets and result in aortic insufficiency [9]. On the other hand, the frequency of valvular dysfunction does not seem to be related to its unique morphology.

Most cases have been found incidentally, and presently QAV is increasingly being identified with the advent of echocardiography, transthoracic or transesophageal [10]. Therefore, a comprehensive investigation for other cardiac abnormalities is required since QAVs have also been discovered in patients with other cardiac abnormalities such as malposition ostium of coronary arteries, hypertrophic cardiomyopathy, or congenital anomalies of the other cardiac valves [11]. Fortunately, no obvious abnormalities were encountered in our patient and so the valve replacement was conducted simply. Furthermore, patients with QAV should be followed closely and surgical intervention should be done as early as possible for those with symptoms secondary to valvular insufficiency.

Symptomatic valvular insufficiency and correction of concomitant anomalies are the surgical indications for patients with QAV. Concerning the QAV, valve replacement remains the mainstay currently; nonetheless, surgical repair is technically achievable in a few selected patients [12]. However, no definite boundary exists between valve replacement and valvoplasty and more studies and long-term follow-up are needed in the future. Because of its vulnerability, proper antibiotic prophylaxis for possible endocarditis is advised before invasive procedures that may cause transient bacteremia [8].

In conclusion, QAV (which is a rare anatomic entity) needs to be taken into consideration, especially in patients without obvious documented etiology. Moreover, it must be considered as a malformation capable of leading to severe valve failure in later life

and a close follow-up with echocardiography is warranted.

REFERENCES

1. Roberts WC. The congenitally bicuspid aortic valve. A study of 85 autopsy cases. *Am J Cardiol* 1970;26:72–83.
2. Hurwitz LE, Roberts WC. Quadricuspid semilunar valve. *Am J Cardiol* 1973;31:623–6.
3. Balington J. *London Medical Gazette*, July 1862.
4. Simonds JP. Congenital malformations of the aortic and pulmonary valves. *Am J Med Sci* 1923;166:584–95.
5. Olson LJ, Subramanian R, Edwards WD. Surgical pathology of pure aortic insufficiency: a study of 225 cases. *Mayo Clin Proc* 1984;59:835–41.
6. Tutarel O. The quadricuspid aortic valve: a comprehensive review. *J Heart Valve Dis* 2004;13:534–7.
7. Timperley J, Milner R, Marshall AJ, et al. Quadricuspid aortic valves. *Clin Cardiol* 2002;25:548–52.
8. Peretz DI, Changfoot GH, Gourlay RH. Four-cusped aortic valve with significant hemodynamic abnormality. *Am J Cardiol* 1969;23:291–3.
9. Feldman BJ, Khandheria BK, Warnes CA, et al. Incidence, description and functional assessment of isolated quadricuspid valves. *Am J Cardiol* 1990;65:937–8.
10. Watanabe T, Hosoda Y, Sasaguri S, et al. A quadricuspid aortic valve diagnosed by transesophageal echocardiography: report of a case. *Surg Today* 1998;28:1102–4.
11. Janssens U, Klues HG, Hanrath P. Congenital quadricuspid aortic valve anomaly associated with hypertrophic nonobstructive cardiomyopathy: a case report and review of the literature. *Heart* 1998;78:83–7.
12. Yener N, Resatoglu A, Elnur el AE, et al. Quadricuspid aortic valve: a chance for repair. *J Heart Valve Dis* 2004;13:860–2.

罕見的四心瓣尖主動脈瓣解剖構造異常 合併主動脈瓣逆流 — 病例報告

張博智¹ 林慶正^{2,3} 李智雄^{2,3}

王寶惠¹ 陳英富^{1,3}

高雄醫學大學附設醫院 ¹心臟血管外科 ²心臟血管內科

³高雄醫學大學 醫學院醫學系

四心瓣尖的主動脈瓣是一種罕見的先天性心臟解剖構造缺陷，常在成人時期造成有症狀的主動脈瓣逆流，進而需要手術置換；我們報告一位有四心瓣尖主動脈瓣合併主動脈瓣逆流的病患，之後成功地接受主動脈瓣置換手術。

關鍵詞：主動脈瓣逆流，四心瓣尖主動脈瓣

(高雄醫誌 2007;23:422-5)

收文日期：96年1月19日

接受刊載：96年2月26日

通訊作者：陳英富醫師

高雄醫學大學附設醫院心臟血管外科

高雄市807三民區自由一路100號