

PERIPHERAL SYMPATHECTOMY FOR RAYNAUD'S PHENOMENON: A SALVAGE PROCEDURE

Wen-Her Wang,¹ Chung-Sheng Lai,^{1,3} Kao-Ping Chang,^{1,3} Su-Shin Lee,^{1,3}
Chih-Chiang Yang,^{2,3} Sin-Daw Lin,^{1,3} and Chia-Ming Liu²

¹Division of Plastic and Reconstructive Surgery, Department of Surgery, Kaohsiung Medical University Hospital, ²Department of Surgery, Kaohsiung Municipal Hsiao-Kang Hospital, and ³Department of Surgery, Faculty of Medicine, College of Medicine, Kaohsiung Medical University, Kaohsiung, Taiwan.

We retrospectively reviewed the effectiveness of peripheral sympathectomy for severe Raynaud's phenomenon. In this study, a total of 14 digits from six patients with chronic digital ischemic change were included. All patients had pain, ulcer, or gangrenous change in the affected digits and were unresponsive to pharmacologic or other nonsurgical therapies. In all cases, angiography showed multifocal arterial lesions, so microvascular reconstruction was unfeasible. Peripheral sympathectomy was performed as a salvage procedure to prevent digit amputation. The results were analyzed according to reduction of pain, healing of ulcers, and prevention of amputation. In 12 of the 14 digits, the ulcers healed and amputation was avoided. In the other two digits, the ulcers improved and progressive gangrene was limited. As a salvage procedure for Raynaud's phenomenon recalcitrant to conservative treatment, peripheral sympathectomy improves perfusion to ischemic digits and enables amputation to be avoided.

Key Words: peripheral sympathectomy, Raynaud's phenomenon
(*Kaohsiung J Med Sci* 2006;22:491-9)

Ischemic disease of the hand and upper extremities may be caused by many different diseases [1]. This difficult and frustrating problem can result in cold intolerance, cool pale fingers, ulcerations, and gangrenous changes. Current conservative treatments, such as smoking cessation, cold avoidance, biofeedback techniques, and nifedipine [1-6] therapy, are sometimes effective, but not uncommonly, the disease progresses and may even necessitate amputation [7].

The term "Raynaud's phenomenon" (RP) is used to describe any form of cold-related vasospasm [6], and is classified as primary or secondary RP [6]. In both primary and secondary RP, exposure to cold or other sympathetic stimuli, such as emotional stress

or pain, may induce vasospasm and cause the finger to become cold and blanched [1-3,6,7]. According to Poiseuille's law, blood flow is directly proportional to the fourth power of the vessel's radius [7]. A slight change in a vessel's radius can have a major effect on blood flow. If it is possible to increase the vessel's radius or attenuate the response to sympathetic stimuli, blood flow to the fingers can be maintained, which may improve the outcome of RP.

Methods of eliminating sympathetic innervation have included drugs, biofeedback techniques, and sympathectomy [1-3,6,7]. Conventional cervical sympathectomy has been used, but the results are disappointing. It has shown only short-term effectiveness because it does not eliminate all sympathetic stimulation to the hand [2,7-9]. Additional sympathetic fibers through the sinuvertebral nerve, the carotid plexus, and the nerve of Kuntz may innervate the hand [2,7,10]. These sympathetic fibers travel along the epineurium of the peripheral nerves and then pass to the adventitia of the vessel when the nerves and vessels

Received: May 12, 2006

Accepted: June 23, 2006

Address correspondence and reprint requests to: Dr Chia-Ming Liu, Department of Surgery, Kaohsiung Municipal Hsiao-Kang Hospital, 482 Shan-Ming Road, Hsiao-Kang District, Kaohsiung 812, Taiwan.

E-mail: gavin.liu@msa.hinet.net

course distally into the arm [11]. At the level of the wrist, the radial and ulnar arteries are innervated by sympathetic branches from the median and ulnar nerves distally; in the palmar and digital levels, the digital nerves supply the sympathetic branch to the neighboring digital vessel. Thorough peripheral sympathectomy has been used to achieve complete sympathectomy [2,8]. In 1953, Mitchell [2] pointed out that sympathetic fibers arborized in the adventitia of vessel. The technique of peripheral sympathectomy may strip the adventitia from the digital arteries for a distance of a few millimeters to several centimeters to completely interrupt sympathetic control of the digital artery [7,8,12,13].

Furthermore, in cases of connective tissue disorder, especially chronic vasculitis, the narrowing of the vessel lumen is often the result of a combined effect of sympathetic hyperactivity and external compression around the vessel [7,14]. External compression is usually caused by the contraction of tissues surrounding the arteries or by the thickened adventitia, usually seen in chronic vasculitis. The technique of peripheral sympathectomy not only interrupts sympathetic control of the vessel involved, but also relieves external compression around the vessel. Theoretically, this method should be more effective than cervical sympathectomy.

In the six cases discussed here, symptoms of RP were relieved after peripheral sympathectomy.

MATERIALS AND METHODS

In this study, six patients admitted to Kaohsiung Medical University Hospital since 1993 were included. All six patients showed symptoms of cold intolerance, cool, pale fingers, or ulcerations. Patients' age, lesion site, symptoms, and preoperative condition are listed in Table 1. Angiography was performed to rule out the possibility of atherosclerotic change or multiple stenoses over digital arteries. Conservative and aggressive medical therapy were unsuccessful. Among the six patients, a total of 14 digits were judged by at least one hand surgeon and one plastic surgeon to be at risk for intractable pain, progressive ischemia, ulcer, or loss of tissue, despite aggressive medical therapy. We performed peripheral sympathectomy on the 14 "digits at risk".

Surgical technique

Under general anesthesia and application of tourniquet, longitudinal skin incisions were made from the proximal palmar crease to the web area. We then approached the bifurcation of the common digital arteries and both sides of the proper digital arteries of the digits at risk. After identification of the vessels, we stripped the adventitia circumferentially from the common digital arteries to the proximal part of both proper digital arteries of the damaged digits under the operative microscope. The length of adventitia

Table 1. Individual patient data

Patient	Age (yr)/sex	Digit	Preoperation			
			Color	Pain	Ulcer	Gangrenous area
1	52/F	Thumb	Cyanosis	+	—	—
		IF	Cyanosis	+	Fingertip	—
		MF	Intermittent change	+	—	—
		RF	Cyanosis	+	—	—
2	64/F	MF	Cyanosis	+	Fingertip	—
		RF	Cyanosis	+	Fingertip	—
		LF	Cyanosis	+	Fingertip	—
3	50/M	MF	Cyanosis	+	Eponychium area	Distal phalanx
		RF	Intermittent change	+	DIP joint area	Fingertip
		LF	Intermittent change	+	—	—
4	30/M	Thumb	Pink	+	—	—
		IF	Pale	+	Fingertip	—
5	68/M	MF	Cyanosis	+	Fingertip	Fingertip
6	38/M	MF	Cyanosis	+	Fingertip	Fingertip

IF = index finger; MF = middle finger; RF = ring finger; LF = little finger; DIP = distal interphalangeal.

stripping was about 3 cm, and if a thrombus was noted in the digital artery, we performed thrombectomy under operative microscope. After the above procedures, the tourniquet was deflated, and the perfusion of damaged digits was observed. If poor perfusion was still noted, we performed adventitia stripping to the level of the proximal interphalangeal joint. After operation, the temperature and color of the digits were observed, and medical treatment, such as vasodilator or heparin, was continued.

Two of our initial cases (cases 5 and 6) underwent adventitia stripping to the level of the digital arteries

from the metacarpophalangeal crease to the distal interphalanx crease (Figure 1). However, vessel caliber is much smaller in this area, the technique is more difficult, and wound healing may be slower, so we modified our procedure to approach the common digital arteries in the other cases.

RESULTS

After peripheral sympathectomy was performed, pain subsided in all patients and the color of all 14

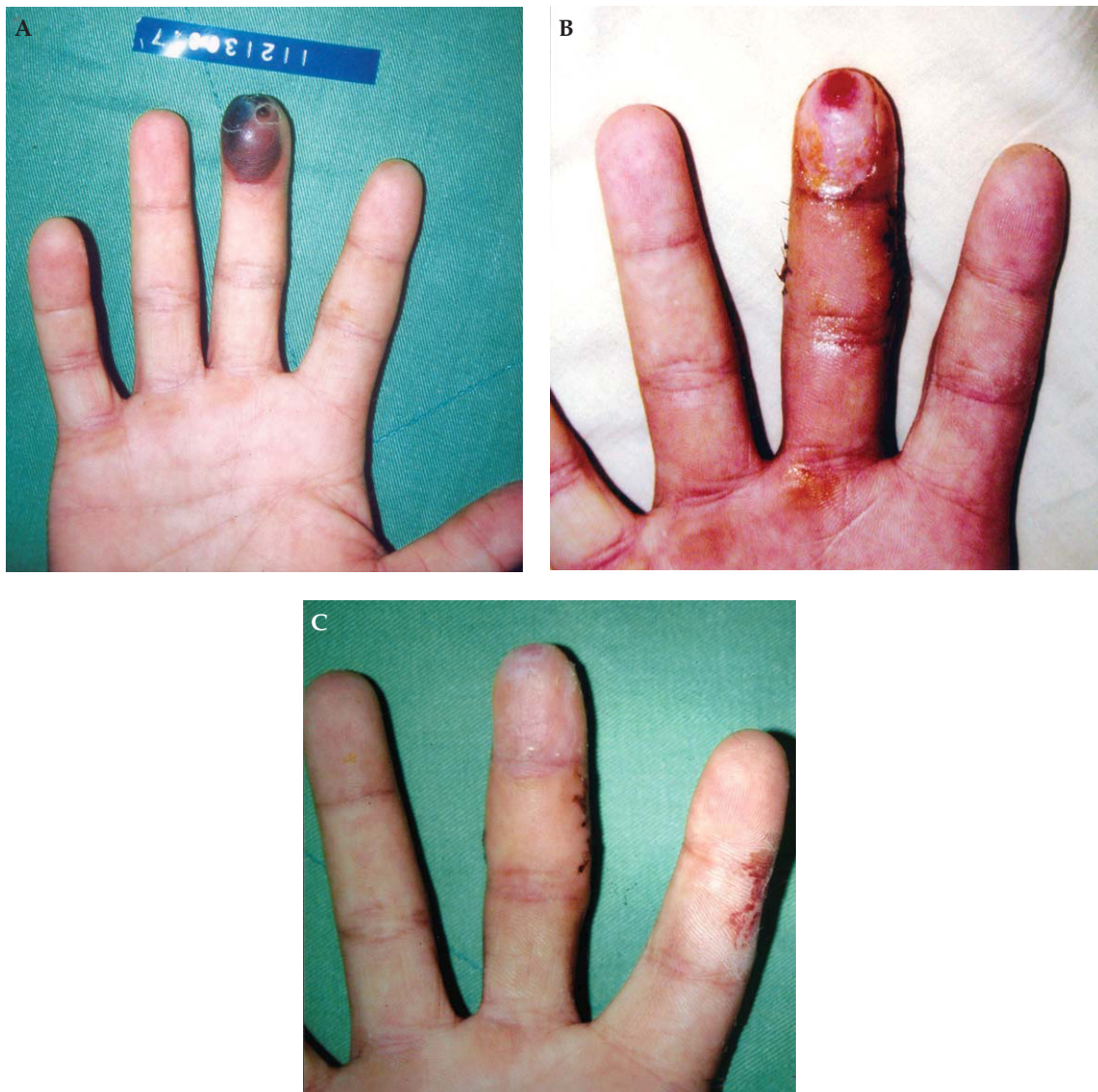

Figure 1. Case 6. (A) Preoperation: cyanosis was noted over the right middle fingertip. Peripheral sympathectomy was performed from the PIP crease to the DIP crease. (B) One week after operation, cyanosis had subsided and a small residual ulcer was noted. (C) One month later, the color of the middle finger had become pink and the wound had completely healed. PIP=proximal interphalangeal; DIP=distal interphalangeal.

Table 2. Results following peripheral sympathectomy

Patient	Follow-up	Digit	Postoperation				Length and level of sympathectomy
			Color	Pain	Ulcer	Progressive gangrene	
1	20 mo	Thumb	Pink	—	—	—	3 cm around bifurcation of common digital artery
		IF	Pink	+ only in cold environment ($\leq 5^{\circ}\text{C}$)	Healed	—	As above and extend to PIP joint + thrombectomy
		MF	Pink	—	—	—	3 cm around bifurcation of common digital artery
		RF	Pink	—	—	—	As above
2	17 mo	MF	Pink	Improved	Healed	—	As above
		RF	Pink	—	Healed	—	As above
		LF	Pink	—	Healed	—	As above
3	5 mo	MF	Cyanosis in distal phalanx	+ only in cold environment ($\leq 5^{\circ}\text{C}$)	Improved	+ in distal phalanx	As above and extend to PIP joint
		RF	Cyanosis in tip	—	Improved	—	3 cm around bifurcation of common digital artery
		LF	Pink	—	—	—	As above
4	9 yr	Thumb	Pink	—	—	—	From MP crease to IP crease
		IF	Pink	—	Healed	—	From MP crease to DIP crease
5	9 yr	MF	Cyanosis in tip	—	Improved	—	As above
6	10 yr	MF	Pink	—	Healed	—	From PIP crease to DIP crease

IF = index finger; MF = middle finger; RF = ring finger; LF = little finger; PIP = proximal interphalangeal; MP = metacarpophalangeal; IP = interphalangeal; DIP = distal interphalangeal.

previously cyanotic fingers became pink. In four of the six patients, representing 12 of the 14 digits, ulceration healed sufficiently to prevent amputation. Details of patients' outcomes and levels of peripheral sympathectomy are listed in Table 2. In case 3, progressive gangrenous change over the distal phalanx of the middle (MF) and ring fingers (RF) were noted preoperatively. After operation, the progressive gangrenous change had stopped and only amputation of the distal phalanx in the MF was required 1 month later. The RF healed spontaneously. Another patient who had previous dry gangrene over the middle fingertip underwent fingertip amputation after peripheral sympathectomy. Cold intolerance was also improved in 12 of the 14 digits.

Case examples

Case 1

A 52-year-old female typist had been suffering from severe painful sensation and change of color in her left hand for 1 week. No obvious history of trauma was noted. The painful sensation was persistent, but could be relieved temporarily in a warm environment.

The color of the digits of her left hand, especially the index finger (IF), changed to pale or cyanotic in a cool environment or after immersion in cold water. Her right hand had no pain or cold intolerance.

The patient had no systemic arthralgia, dysphagia, skin tightening, xerophthalmia, or xerostomia. No previous exposure to trauma or frostbite over the left hand was noted. The patient was a nonsmoker and had no history of diabetes mellitus or carpal tunnel syndrome. Physical examination showed cyanotic change, poor capillary refilling, and numbness over the first to fourth digits of the left hand. Clubbed IF was noted (Figure 2A). Slight thenar muscle atrophy was noted on the left hand. Routine blood tests, erythrocyte sedimentation rate, prothrombin time, partial thromboplastin time, and other ordinary laboratory data were in the normal ranges; rheumatic factor and antinuclear antibody were negative.

After admission, she received prostaglandin E₁ for treatment and her hand was maintained in a warm environment with a heater. The pain subsided temporarily, but severe pain resumed 2 days later.

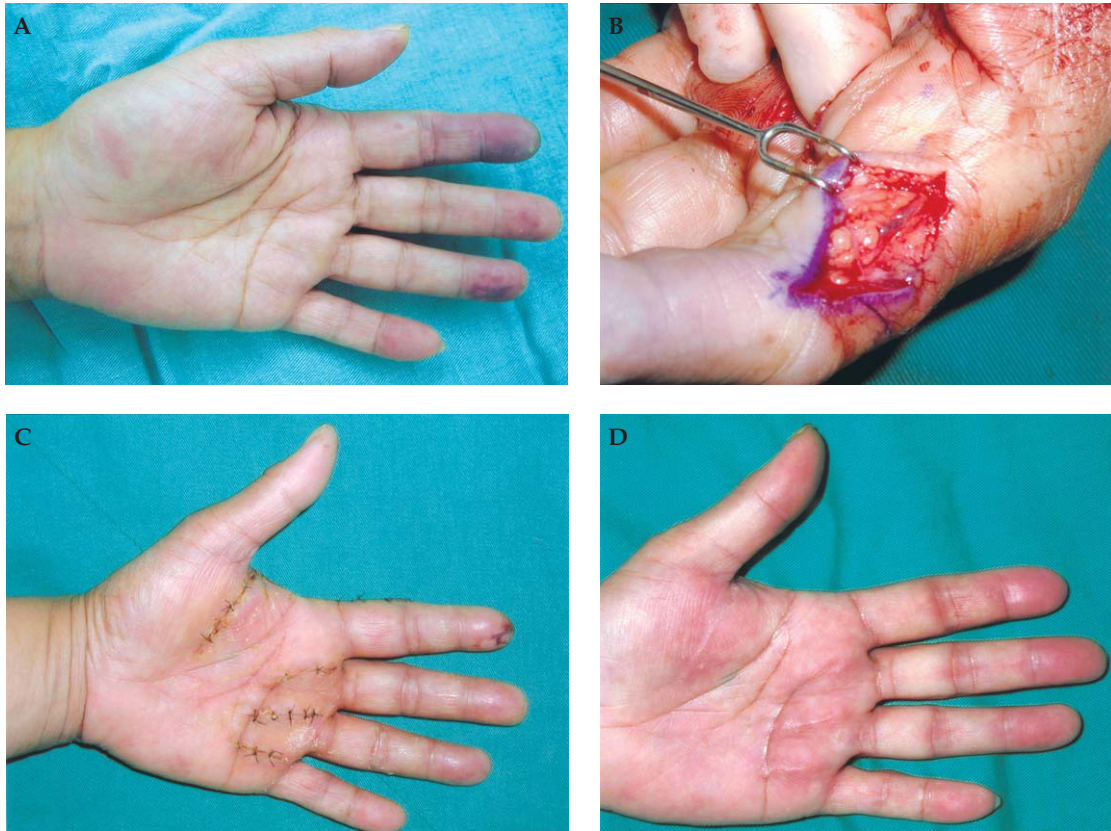


Figure 2. Case 1. (A) Painful cold sensation with color change and cyanosis over the first to fourth digits of the left hand. (B) Longitudinal incision in the web area was performed to identify the digital artery. Thrombus was noted over the second radial proper digital artery. Peripheral sympathectomy and thrombectomy were performed under operative microscope. (C) Ten days after peripheral sympathectomy, pink color and warm temperature were noted in the first to fourth digits of the left hand. Painful sensation had subsided and the incision wound was healing well. (D) Follow-up at 1 year after the operation: all symptoms had subsided; there was no pain, no intermittent color change, and the temperature of the first to fourth digits was warm.

Angiography showed the following: (1) no contrast opacification in the superficial palmar arch and digital arteries of the left thumb and IF; (2) increased collateral branches in the ulnar side of the wrist; and (3) lumen narrowing in the ulnar and radial arteries (Figure 3A). Peripheral arterial occlusion disease was impressed and heparin, dextran, and antiplatelet medication were administered to salvage the digits. Unfortunately, the pain increased and the color of the first to fourth digits of her left hand became increasingly cyanotic. We then tried advanced combination therapy with other drugs, including a calcium-channel blocker (nifedipine), an α -blocker, an analgesic, and an anxiolytic. However, no improvement of the symptoms was noted. The digits became more painful, more cyanotic, and cooler. At this point, we concluded that surgical intervention was necessary. We performed adventitia stripping over the left first to fourth common digital arteries with extension to the

proper digital artery of the IF. Thrombectomy was performed in the proper digital artery of the IF because a thrombus in this area was noted (Figure 2B).

After peripheral sympathectomy, the color of the first and third to fifth digits of the left hand became pink within 6 hours, the digits became warmer, and the painful sensation decreased. Unfortunately, the color of the IF remained cyanotic and colder in temperature. The pain persisted in the IF. On the 2nd post-operative day, the color of the IF dramatically changed to pink and the temperature increased. The tip of the IF was still mildly cyanotic, but the painful sensation was completely relieved. No intermittent color change in the left hand was noted thereafter. The patient was satisfactorily discharged on the 5th day after the operation.

After discharge, the patient had regular follow-up examinations in our outpatient department. A small preoperative ulcer measuring about 0.4×0.3 cm in the index fingertip healed completely within 2 weeks

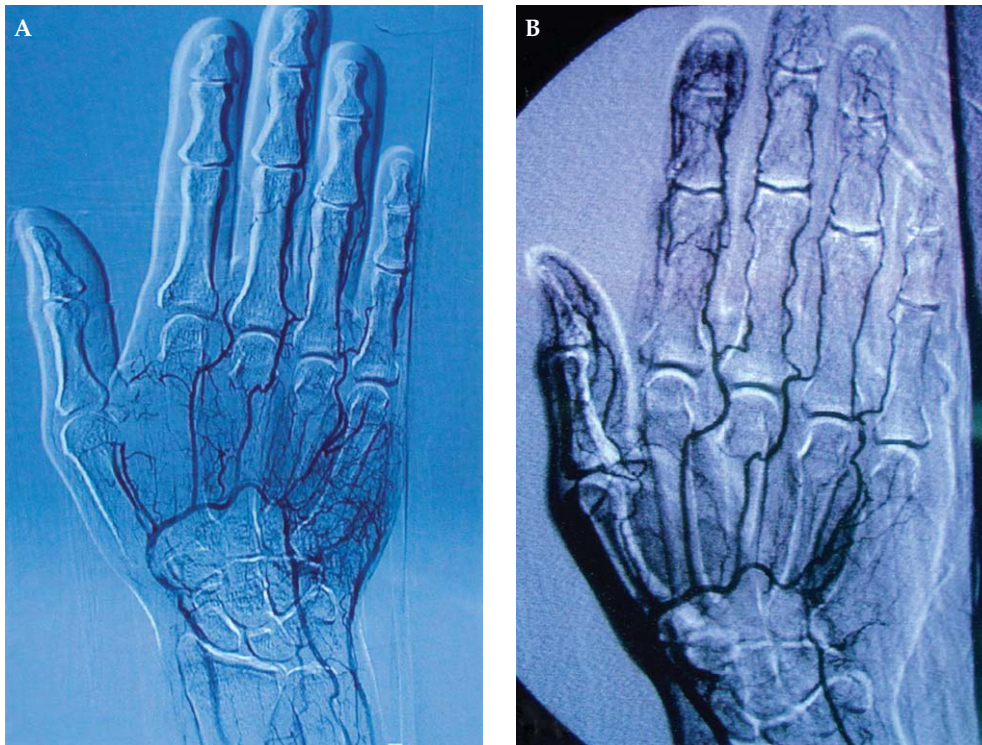


Figure 3. (A) Angiography showed no contrast opacification in the superficial palmar arch. There is total occlusion in both proper digital arteries of the left thumb and radial proper digital artery of the second to fifth digits of the left hand. Multifocal stenosis was noted in the ulnar and radial arteries. (B) Follow-up angiography 1 year after operation showed that the previous occluded digital arteries are patent.

(Figure 2C). At the 1-year follow-up examination, symptoms were completely relieved (Figure 2D), and angiography showed patency of the previously occluded digital arteries (Figure 3B).

Case 2

A 64-year-old woman had been suffering from skin necrosis and chronic ulcers with infection of the digits for several years. As in case 1, this patient suffered from cyanosis and sensitivity to cold temperatures in the third to fifth digits of her right hand. Angiography showed multifocal stenosis over all common digital and radial arteries in the right hand and complete occlusion over both proper digital arteries of the right third and fourth digits. Conservative treatment with antiplatelet medication, prostaglandin E₁, and heat application were attempted without success. After peripheral sympathectomy was performed over the right third and fourth common digital arteries, cyanosis improved, and the pain decreased. Capillary refilling also improved. The patient was discharged on the 6th postoperative day.

DISCUSSION

The human digit is a sensory organ that serves as a thermoregulator [15]. Depending on the temperature of the environment, the blood flow in a digit may increase or decrease. The magnitude of difference in blood flow increases if a patient has vasospastic disease. This may be due to hyperactivity of sympathetic tone in the cold environment. Conservative methods of treating this disease include calcium channel blockade, α -blocker, vasodilator, and cold avoidance. These remedies often achieve a fair effect but, sometimes, the symptoms of ischemia progress.

Some therapeutic procedures exist for the patient with chronic ischemia of the digits once conservative measures have failed. In cases of severe pain or non-healing digital ulcers, surgical amputation may be necessary. However, in these severe cases, ischemic change may involve several digits, so amputation can lead to major loss of function and cosmetic problems [7]. To resolve these issues, microvascular reconstruction or sympathectomy has been used [1,2].

Microvascular reconstruction with interposition vein grafting from the distal radial or ulnar artery to the common digital arteries has been used in patients with angiographic findings of occlusion of the distal radial and ulnar arteries [2]. This procedure may improve pulse volume and prompt resolution of pain with ulcer healing in the involved digits. However, this technique is not appropriate for all cases of digital ischemia because multifocal stenosis may occur in the common digital arteries of patients with collagen vascular disorders or atherosclerosis. According to previous studies [2,16], this procedure is only recommended under the following conditions: (1) adequate distal run-off is shown on preoperative views of the common digital arteries on angiography; and (2) satisfactory backflow from the common digital arteries is noted at the time of surgical exploration.

Sympathectomy has been proposed to eliminate exaggerated sympathetic vasoconstrictive responses in patients with RP [1–3]. Historically, cervical sympathectomy was a common procedure for RP if all conservative treatments had failed. Unfortunately, this procedure provides only temporary improvement, and recurrence in long-term follow-up is disappointingly frequent [8,17]. Clinical experience suggests that RP in the feet can be ameliorated by sympathectomy [6], but in the hands, any benefit is only short term and does not affect the prognosis of the disease. This may be due to the fact that the hand is innervated not only by the cervical sympathetic chain, but also by the carotid plexus, as well as the nerve of Kuntz [2,7,10,11].

Because cervical sympathectomy cannot remove all sympathetic stimulation, peripheral sympathectomy has been suggested as a means to interrupt the periarterial sympathetic fibers and digital nerve branches to the common and proper digital arteries [7,8]. With this method, all sympathetic vasoconstrictive control of the digital artery is blocked. This leads to a more distal interruption of sympathetic innervation to decrease norepinephrine release at the myoneural junction in the vessel wall, and thus eliminates vasospasm and dilates arterial smooth muscle [15].

In 1980, Flatt was the first to suggest this procedure for the treatment of RP [8]. He stripped the adventitia from the common digital arteries and separated the digital nerves from these vessels for a length of 2–4 mm.

Wilgis modified this technique by removing adventitia more distally and increasing the length of adventitial stripping to 2 cm [5]. He proposed that

the more distal the peripheral sympathectomy, the more effective the result. Wilgis' study also showed that the response to surgery may not be immediate because the circulating humoral component of sympathetic activity may be present in the digits [13]. However, the fingers usually became warmer in temperature within 24 hours. El-Gammal and Blair modified Wilgis' technique by additional stripping of the adventitia from the radial and ulnar arteries in the wrist [18]. Egloff et al stripped the adventitia from the common digital artery and proximal part of the digital artery for 5–10 mm [19].

In accordance with Wilgis' technique, we extended peripheral sympathectomy to the length of 3 cm. In severed digits, we further stripped the adventitia circumferentially to the level of the proximal interphalangeal joint. We abandoned microvascular reconstruction with interposition vein grafting due to multifocal stenosis, but we performed thrombectomy if thrombus was found. In our study, the ulnar and radial arteries were not approached, and the outcome in all digits was excellent. The IF in case 1 was still ischemic and cyanotic after operation but improved dramatically on the 2nd day. This finding was consistent with Wilgis' study.

In the past, preoperative evaluation included a cold stress test before and after patients received local anesthetic block or sympathetic blockade. This procedure is recommended only for patients with primary RP who have demonstrated increased perfusion by local anesthetic block or sympathetic blockade [13]. However, in 1991, Jones found that patients with connective tissue disorder have greater proliferation of fibrous tissue around the superficial palmar arch and digital neurovascular bundles [16]. In these patients, external compression may contribute to the ischemic hand. Peripheral sympathectomy can remove not only sympathetic control, but also periadventitial fibrous tissue [7,14,16]. In his series of studies, patients with connective tissue disorder also showed marked improvement.

McCall et al [7] also pointed out that thickened adventitia is often seen in patients with chronic vasculitis. A combination of sympathetic activity and external compression causes narrowing of the vessel lumen. They performed repeated sympathectomy on a patient with scleroderma. During the second operation, no regenerated sympathetic fibers were noted, so they simply released the scar tissue around the digital arteries with satisfactory results. Yee et al performed

adventitial stripping in patients who responded poorly to preoperative sympathetic nerve blockade [14]. Their results were also satisfactory. According to these studies, a poor response to preoperative cold stress test with local anesthesia or sympathetic blockade may not be a contraindication to peripheral sympathectomy.

In 1995, Koman et al evaluated the microcirculatory effects in patients with secondary RP after peripheral sympathectomy [15]. They found that the temperature, which reflected the total blood flow in the digits, was not significantly higher, but nutritional flow was greater. Furthermore, the rapid decline in digital temperature during preoperative cold stress test did not occur after operation. This result may be due to the fact that in the microcirculation of human digits [7,15], arteriovenous anastomoses control thermoregulation, and capillaries control the nutritional blood flow, which reflects the cutaneous perfusion. Peripheral sympathectomy may improve nutritional blood flow rather than increase arteriovenous shunting. A sufficient nutritional flow can maintain cellular integrity and tissue viability. This would explain the reduction in symptoms and improvement of wound healing even when the temperature is not significantly higher.

Several studies of peripheral sympathectomy have been reported in the treatment of RP. The results have been encouraging [5,7,8,12-16,18,19]. These studies indicate that this procedure is effective in relieving symptoms and improving cold intolerance. However, patients undergoing this treatment have not been completely asymptomatic. Recurrent digit ulcerations have been noted in some patients. Even though cold intolerance may be reduced, it may still be present to some degree, especially when the temperature is below 5-10°C [7]. Although this procedure cannot restore normal tolerance to cold, our study indicates that it is still very effective in improving the perfusion of ischemic digits, and it can be used as a salvage procedure to prevent amputation of digits.

REFERENCES

1. Landry GJ, Edwards JM, Porter JM. Current management of Raynaud's syndrome. *Adv Surg* 1996;30:333-47.
2. Miller LM, Morgan RF. Vasospastic disorders: etiology, recognition, and treatment. *Hand Clin* 1993;9:171-87.
3. Seibold JR, Allegar NE. The treatment of Raynaud's phenomenon. *Clin Dermatol* 1994;12:317-21.
4. Ward WA, van Moore A. Management of finger ulcers in scleroderma. *J Hand Surg* 1995;20:868-72.
5. Wilgis EFS. Evaluation and treatment of chronic digital ischemia. *Ann Surg* 1981;193:693-8.
6. Belch J. Raynaud's phenomenon. *Cardiovasc Res* 1997; 33:25-30.
7. McCall TE, Petersen DP, Wong LB. The use of digital artery sympathectomy as a salvage procedure for severe ischemia of Raynaud's disease and phenomenon. *J Hand Surg* 1999;24:173-7.
8. Flatt AE. Digital artery sympathectomy. *J Hand Surg* 1980;5:550-6.
9. Gahhos F, Ariyan S, Frazier WH, et al. Management of sclerodermal finger ulcers. *J Hand Surg* 1984;9:320-7.
10. Pick J. *The Autonomic Nervous System*. Philadelphia: JB Lippincott, 1970:341-9.
11. Morgan RF, Reisman NR, Wilgis EFS. Anatomic localization of sympathetic nerves in the hand. *J Hand Surg* 1983;8:283-8.
12. Jones NF, Imbriglia JE, Steen VD, et al. Surgery for scleroderma of the hand. *J Hand Surg* 1987;12:391-400.
13. Wilgis EFS. Digital sympathectomy for vascular insufficiency. *Hand Clin* 1985;1:361-7.
14. Yee AM, Hotchkiss RN, Paget SA. Adventitial stripping: a digit saving procedure in refractory Raynaud's phenomenon. *J Rheumatol* 1998;25:269-76.
15. Koman LA, Smith BP, Pollock FE Jr, et al. The microcirculatory effects of peripheral sympathectomy. *J Hand Surg* 1995;20:709-17.
16. Jones NF. Acute and chronic ischemia of the hand: pathophysiology, treatment, and prognosis. *J Hand Surg* 1991;16:1074-83.
17. Claes G, Drott G, Gothberg G. Thoracoscopy for autonomic disorders. *Ann Thorac Surg* 1993;56:715-6.
18. EI-Gammal TA, Blair WF. Digital periarterial sympathectomy for ischemic digital pain and ulcers. *J Hand Surg* 1991;16:382-5.
19. Egloff DV, Mifsud RP, Verdant C. Superselective digital sympathectomy in Raynaud's phenomenon. *Hand* 1983; 15:110-4.

末梢交感神經切除術治療雷諾氏現象： 一種拯救手術

王文禾¹ 賴春生^{1,3} 張高評^{1,3} 李書欣^{1,3}

楊錦江^{2,3} 林幸道^{1,3} 劉家銘²

¹高雄醫學大學附設醫院 重建整形外科

²高雄市立小港醫院 外科

³高雄醫學大學 醫學院醫學系外科學

我們回顧性地評論末梢交感神經切除術治療嚴重雷諾氏現象的效果。本研究包含六位罹患慢性手指缺血性變化的十四隻手指。所有病例的患肢都有疼痛、潰瘍、或壞疽變化，而且都對藥物治療或非手術性治療無效。所有病例的血管攝影顯示指動脈多灶性損害，因此微細血管的重建是不可行的。末梢交感神經切除術扮演一種預防手指截肢的拯救手術。我們根據疼痛的減輕、潰瘍的癒合、及截肢的預防來分析研究的結果。在十四隻手指中的十二隻，其潰瘍癒合而免除被截肢的命運。其它兩隻手指的潰瘍獲得改善，且進行性的壞疽變化也被限制住了。

關鍵詞：末梢交感神經切除術，雷諾氏現象

(高雄醫誌 2006;22:491-9)

收文日期：95年5月12日

接受刊載：95年6月23日

通訊作者：劉家銘醫師

高雄市立小港醫院外科

高雄市812小港區山明路482號