

# TUBERCULOUS PERICARDIAL ABSCESS: A CASE REPORT

Tsung-Hsien Lin, Chaw-Chi Chiu,<sup>1</sup> Chih-Hsin Huang, Kun-Bow Tsai,<sup>2</sup>  
and Sheng-Hsiung Sheu

Division of Cardiology, Department of Internal Medicine, <sup>1</sup>Division of Cardiovascular Surgery,  
Department of Surgery, and <sup>2</sup>Department of Pathology, Kaohsiung Medical University,  
Kaohsiung Medical University Hospital, Kaohsiung, Taiwan.

We present the case of a 71-year-old diabetic man who came to us complaining of dyspnea for 1 month. Chest X-ray showed cardiomegaly and bilateral pleural effusion. Echocardiography showed a pericardial cystic mass with external compression of the right ventricle. Because of clinically impending cardiac tamponade, we performed urgent sternotomy and removed the pericardial mass without event. Pathologic examination of the excised pericardial specimen showed caseous necrosis compatible with tuberculosis infection. The patient was put on a 1-year treatment regimen of anti-tuberculosis medication. This case is an important reminder that tuberculosis can occur as a pericardial abscess.

**Key Words:** pericardial abscess, tuberculosis, mediastinum mass, caseous necrosis, pericardium  
(*Kaohsiung J Med Sci* 2005;21:322-5)

Although tuberculosis (TB) is becoming less prevalent, it remains a clinically challenging endemic disease in developing countries. Although it is usually associated with the lungs, as many as one-third of cases can involve other organs. In pericardial tuberculosis, which is rare, most patients develop pericardial effusion and some may ultimately develop the symptoms of cardiac tamponade. Little has been reported on TB pericardial abscess complicated by cardiac tamponade. Herein, we report a diabetic patient who came to us with symptoms typical of cardiac tamponade that was caused by a TB pericardial abscess. We discuss this case in light of previous findings.

## CASE PRESENTATION

A 71-year-old hypertensive man with diabetes controlled without regular use of an oral hypoglycemic agent visited our cardiovascular clinic. He complained of progressive

dyspnea on exertion for 1 month. He had also experienced cough with a little sputum. No fever was observed.

The patient's baseline electrocardiogram showed sinus tachycardia, left ventricle hypertrophy, and a non-specific ST-T abnormality. Chest X-ray showed cardiomegaly and bilateral pleural effusion without a remarkable intrapulmonary lesion (Figure 1A). He was admitted to our unit under the impression of congestive heart failure.

The patient had a blood pressure of 140/80 mmHg and a regular pulse of 94/min. Auscultation revealed a grade I systolic murmur over the apex and decreased bilateral lower lung breathing sounds. The other positive physical examination findings were engorged jugular vein, hepatomegaly, and bilateral lower-leg edema.

Routine laboratory tests showed elevated C-reactive protein (26.4 mg/L), lactate dehydrogenase (465 m/L), and fasting glucose (7.326 mmol/L). Normocystic anemia (hemoglobin 110 g/L, mean corpuscular volume 87.7 fL) and hypoalbuminemia (3.42 mg/dL) were also found. Sputum examination was negative for acid-fast stain (AFS), TB polymerase chain reaction, TB culture, and malignant cells. Thoracocentesis during admission gave an exudative pleural effusion that was negative for AFS and TB culture.

Transthoracic echocardiography showed a 3.9 × 9.4-cm cystic mass adjacent to and compressing the right ventricle (Figure 1B). Computed tomography revealed a thickened

Received: March 3, 2005

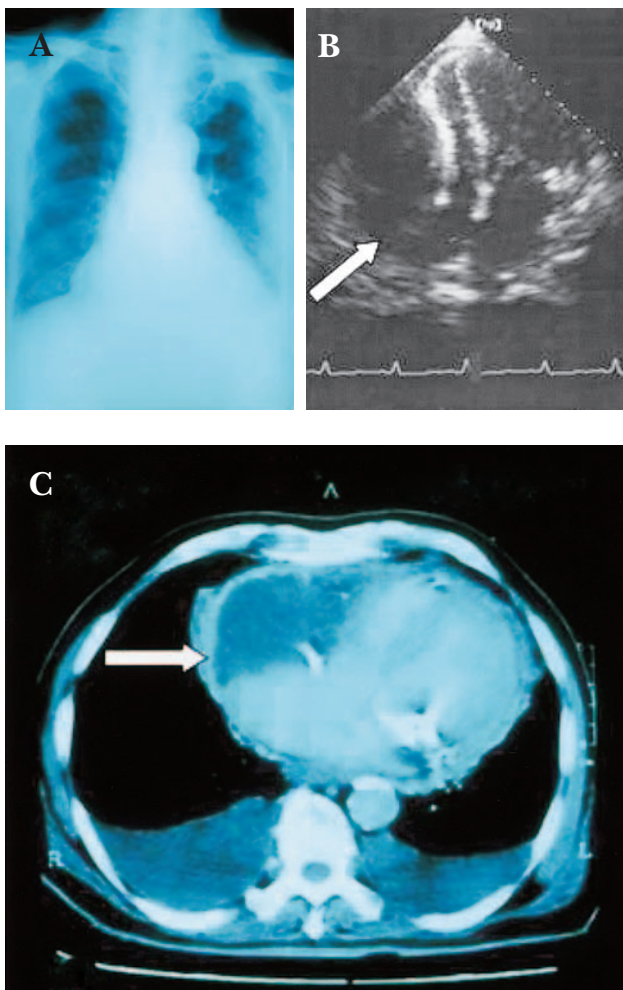
Accepted: April 27, 2005

Address correspondence and reprint requests to: Dr. Sheng-Hsiung Sheu, Division of Cardiology, Department of Internal Medicine, Kaohsiung Medical University Hospital, 100 Shih-Chuan 1<sup>st</sup> Road, Kaohsiung 807, Taiwan.

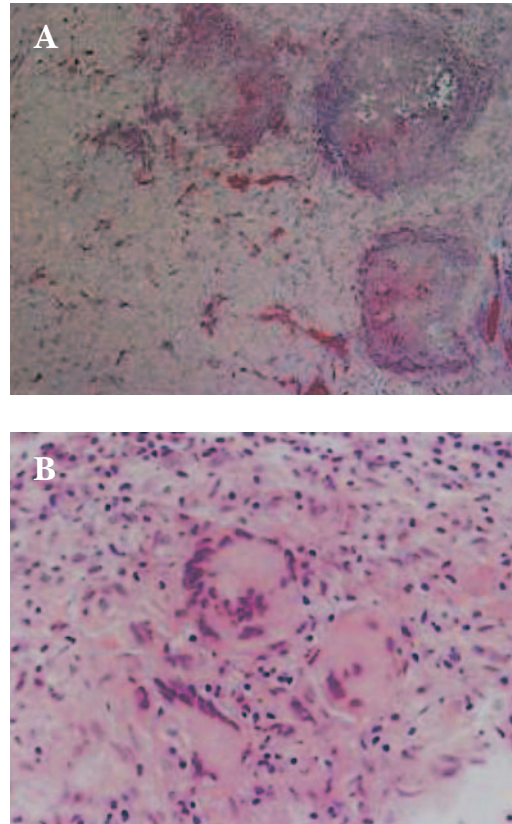
E-mail: Sheush@kmu.edu.tw

pericardium and a roughly 10 × 7 × 7-cm cystic mass in the right anterior-inferior pericardium (Figure 1C).

Because the patient's clinical symptoms were progressively deteriorating, we consulted a cardiovascular surgeon who suggested urgent surgery to relieve the mass-related external compression. The patient underwent midline sternotomy and removal of the thickened cystic mass. The cystic lesion was located in front of the heart and its wall could not be separated from the pericardium. The operative procedures were uneventful. The pathology of the excised pericardial specimen showed caseating granuloma (Figure 2), which is compatible with TB infection. A combination of four anti-TB medications was prescribed for 1 year. The patient, who received regular cardiovascular



**Figure 1.** (A) Chest X-ray showing cardiomegaly and bilateral pleural effusion. (B) Transthoracic echocardiography of a cystic mass (arrow) adjacent to and compressing the right ventricle. (C) Computed tomography reveals a thickened pericardium and cystic mass (arrow) in the right anterior-inferior pericardial cavity.



**Figure 2.** Pathology of the excised pericardial specimen shows giant cell and central caseous necrosis (A, × 4; B, × 40).

follow-up, did not complain of any discomfort and had an uneventful recovery.

## DISCUSSION

TB is usually classified as pulmonary or extrapulmonary. More than 80% of all cases of TB are limited to the lungs. In order of decreasing frequency, the extrapulmonary sites most commonly involved in TB are the lymph nodes, pleura, genitourinary tract, bones and joints, meninges, and peritoneum, though virtually all organ systems can be affected. There have been few reports of pericardial involvement, and most that do discuss it focus on the pericardial effusion rather than the pericardial abscess.

True pericardial cysts are generally considered to be congenital in origin, occurring in approximately 1 in 100,000 people. Acquired pericardial cysts or diverticulae secondary to inflammatory pericarditis have been reported. Loehr surveyed the literature and classified pericardial cystic lesions into true cysts of congenital origin: acquired cysts following hematoma, neoplasm, or parasitic disease;

and pseudocysts (i.e. pericardial diverticulae and encapsulated pericardial fluid) [1]. According to our imaging and operative findings, our patient's pericardial cystic lesion was thought to be a TB-related acquired abscess.

Few papers have reported TB as the cause of a pericardial abscess. Lesar et al reported an unusual cause of left mediastinal mass in two cases as pericardial tuberculoma [2]. Cushing, who reviewed 39 examples of pericardial diverticulae from the literature, added one case that apparently followed tuberculous pericarditis [3]. Thirithuvathas et al reported a 2-year-old child suffering from a huge prepericardial tuberculous abscess [4]. Recently, Oh et al, in a review of the surgical pathologies related to the parietal pericardium, reported none to be TB related [5].

Most pericardial cysts and masses have been discovered incidentally on routine chest radiographs and are seen along the border of the heart as an elevation of the diaphragm, enlarged cardiac silhouette, or abnormal shadow. Transthoracic and transesophageal echocardiography can differentiate between cystic and solid masses and define their relationship to cardiac chambers. Computed tomography and magnetic resonance imaging may be more helpful in defining size and cause [6–8]. True pericardial cyst, bronchogenic cyst, lymphatic cyst, esophageal cyst, aneurysm of the left ventricle, Morgagni diaphragmatic hernia, hydatid disease, other mediastinum, and heart tumors should be taken into consideration and differentiated.

Treatment of a pericardial mass is dependent on its cause and clinical course. Surgery is usually unnecessary except in cases of medical failure or worsening symptoms such as cardiac tamponade. Treatment aims to eliminate the mass, relieve symptoms, and possibly allow histologic examination. Our patient underwent surgery after he was

hospitalized for his worsening condition and initial signs of cardiac tamponade. After the cardiac compression was relieved, his TB infection was eradicated and its recurrence prevented with anti-TB medication.

Finally, this case is an important reminder that TB can occur as a pericardial abscess without significant lung involvement. However, the best way to diagnose TB is to be aware that it varies clinically and remain alert for the possibility.

## REFERENCES

1. Loehr WM. Pericardial cysts. *Am J Roentgenol Radium Ther Nucl Med* 1952;68:584–609.
2. Lesar MS, Orcutt J, Wehunt WD, et al. Pericardial tuberculoma. An unusual cause of mediastinal mass. *Radiology* 1981; 138:309–10.
3. Cushing EH. Diverticulum of the pericardium. *Arch Intern Med* 1937;59:56.
4. Thirithuvathas AJ, Ravikumar S, Gnanaseelan T. Huge prepericardial tuberculous abscess in a 2-year-old child. *J Pediatr Surg* 1989;24:1124.
5. Oh KY, Shimizu M, Edwards WD. Surgical pathology of the parietal pericardium: a study of 344 cases (1993–1999). *Cardiovasc Pathol* 2001;10:157–68.
6. D'Silva SA, Nalladaru ZM, Dalvi BV, et al. MRI as guide to surgical approach in tuberculous pericardial abscess. Case report. *Scand J Thorac Cardiovasc Surg* 1992;26:229–31.
7. Cademartiri F, Nieman K, Mollet N, et al. Images in cardiovascular medicine. Sixteen-row multislice computed tomography of tuberculous pericardial abscess. *Ital Heart J* 2003;4:575–6.
8. Gulati GS, Sharma S. Pericardial abscess occurring after tuberculous pericarditis: image morphology on computed tomography and magnetic resonance imaging. *Clin Radiol* 2004;59:514–9.

# 結核性心包膜膿瘍

林宗憲<sup>1</sup> 邱肇基<sup>2</sup> 黃智興<sup>1</sup> 蔡坤寶<sup>3</sup> 許勝雄<sup>1</sup>

高雄醫學大學附設中和紀念醫院 <sup>1</sup>心臟血管內科 <sup>2</sup>心臟血管外科 <sup>3</sup>病理科

我們報告一位 71 歲罹患糖尿病男性，其主訴一個月來有氣促現象。胸部 X 光顯示心臟擴大及兩側肋膜積水。心臟超音波顯示心臟旁有一水泡狀囊腫且壓迫右心室。因為臨床上顯現瀕臨心包膜填塞的症狀，因此我們施行手術並成功移除囊腫。病理檢查顯示如同肺結核感染後所呈現的乳酪狀壞死。病人之後接受一年的抗結核藥治療。這個病歷提醒我們結核感染可以以心包膜膿瘍表現。

**關鍵詞：**心包膜膿瘍，肺結核，縱膈腔腫，乳酪狀壞死，心包膜  
(高雄醫誌 2005;21:322-5)

收文日期：94 年 3 月 3 日

接受刊載：94 年 4 月 27 日

通訊作者：許勝雄醫師

高雄醫學大學附設中和紀念醫院心臟血管內科

高雄市 807 三民區十全一路 100 號