

CLUBBED FINGERS AND HYPERTROPHIC OSTEOARTHROPATHY IN A PATIENT WITH SQUAMOUS CELL CARCINOMA OF THE LUNG

Wen-Chi Yang, Shih-Chang Lin, Ta-Chih Liu,¹ Chung-Jen Chen, Jeng-Hsien Yen, Tsan-Teng Ou, Hong-Wen Liu, and Wen-Chan Tsai
Departments of Internal Medicine and ¹Hematology, Kaohsiung Medical University, Kaohsiung, Taiwan.

Hypertrophic osteoarthropathy (HOA) is characterized by clubbed fingers and periosteal new bone formation. Etiologically, it can be divided into primary and secondary HOA, but its pathogenesis is uncertain. We report a 42-year-old male patient who suffered from painful clubbing fingers and toes. Serial examinations revealed periosteal new bone formation in the four limb long bones and a solid mass lesion in the right upper lung field. Pathologic examination of the resected mass lesion showed squamous cell carcinoma. After surgery and chemotherapy, the severity of clubbed fingers decreased and joint pain improved. Follow-up bone scan also suggested regression of the uptake of radioactivity in the four limb bones. We concluded that the HOA in this case was probably caused by lung cancer.

Key Words: hypertrophic osteoarthropathy, clubbing fingers, squamous cell carcinoma, periosteal new bone formation
(*Kaohsiung J Med Sci* 2003;19:183-7)

Hypertrophic osteoarthropathy (HOA) is characterized by clubbing of the digits, periosteal new bone formation, and synovial effusion in the more advanced stages. It can be divided into primary and secondary HOA by etiology. Here, we report a patient with lung cancer presenting a picture of HOA.

CASE PRESENTATION

A 42-year-old male was in good health until he suffered from bilateral knee joint pain, especially in the left

knee, from July 2000. He visited the outpatient department and took non-steroidal anti-inflammatory drugs with limited effect. Bilateral lower leg edema, elbow pain, wrist pain, and limited motion developed 7 months later. Clubbed fingers and toes were also noted. He was referred to Kaohsiung Medical University Hospital (KMUH) in July 2001. Laboratory data showed elevated immunoglobulin A (IgA), erythrocyte sedimentation rate (ESR), and C-reactive protein (CRP). He was admitted to the rheumatology ward for further evaluation and management. Family history revealed that his mother had died of gastric carcinoma and his father was a victim of stroke.

After admission, physical examination revealed no significant abnormality except clubbing in the fingers and toes (Figure 1A). Roentgenography revealed periosteal new bone formation over the long bones. Bone scan (August 14, 2001) showed significant pericortical uptake throughout the long bones in all four limbs (Figure 2A) that was compatible with the clinical impression of hypertrophic pulmonary

Received: January 7, 2002 Accepted: September 5, 2002
Address correspondence and reprint requests to: Dr. Wen-Chan Tsai, Division of Allergy, Immunology and Rheumatology, Department of Internal Medicine, Chung-Ho Memorial Hospital, Kaohsiung Medical University, 100 Shih-Chuan 1st Road, Kaohsiung 807, Taiwan.
E-mail: a2203968@ms13.hinet.net

osteoarthritis. Chest roentgenography showed a lung mass over the right upper lobe. Chest computerized tomography (August 14, 2001) confirmed the presence of a tumor mass over the right upper lobe with right hilum involvement and small lymph nodes in the pretracheal region. Bronchoscopic biopsy revealed that the mass was non-keratinizing squamous cell carcinoma (SCC).

Laboratory examinations showed an inflammatory reaction, with CRP of 57.8 µg/ml (normal, < 6.0 µg/ml). ESR was 135 mm/hr (normal, < 10 mm/hr). Immunoglobulin survey showed IgG of 1,450 mg/dl (normal, 1,404.2 ± 48.7 mg/dl), IgA of 439 mg/dl (normal, 253.1 ± 17.3 mg/dl), and IgM of 48.1 mg/dl (normal, 151.4 ± 12.2 mg/dl). Complement 3 (C3) was 129 mg% (normal, 104.3 ± 21.2 mg%) and C4 was 50.4 mg% (normal, 25.0 ± 7.8 mg%). Tests for antinuclear antibody, anti-dsDNA, anti-ribonucleoprotein, human lymphocyte antigen B27, and rheumatoid factor were all negative. Thyroid function was normal. Tumor

markers were as follows: SCC was < 1.0 ng/ml (normal, < 2.6 ng/ml), TPA (tumor polypeptide antigen) was 55.4 U/L, and hGH (human growth hormone) was 0.11 ng/ml (normal is 0–5 ng/ml). Insulin-like growth factor-1 was 110.1 ng/ml and CEA (carcinoembryonic antigen) was 0.7 ng/ml (normal, < 6). Knee joint synovial fluid showed a cell count of 144, and polymorphonucleocytes/monomorphonucleocytes was 13/87%, which was considered non-inflammatory joint fluid.

The patient was transferred for surgery under the diagnosis of lung carcinoma with HOA. Right upper lobectomy and mediastinal lymph node dissection were performed subsequently. Pathologic findings were compatible with previous reports and revealed patterns of poorly differentiated squamous cell carcinoma with reactive hyperplastic lymph nodes (15/15).

Follow-up bone scan after treatment revealed regression of diffuse pericortical uptake (Figure 2B).

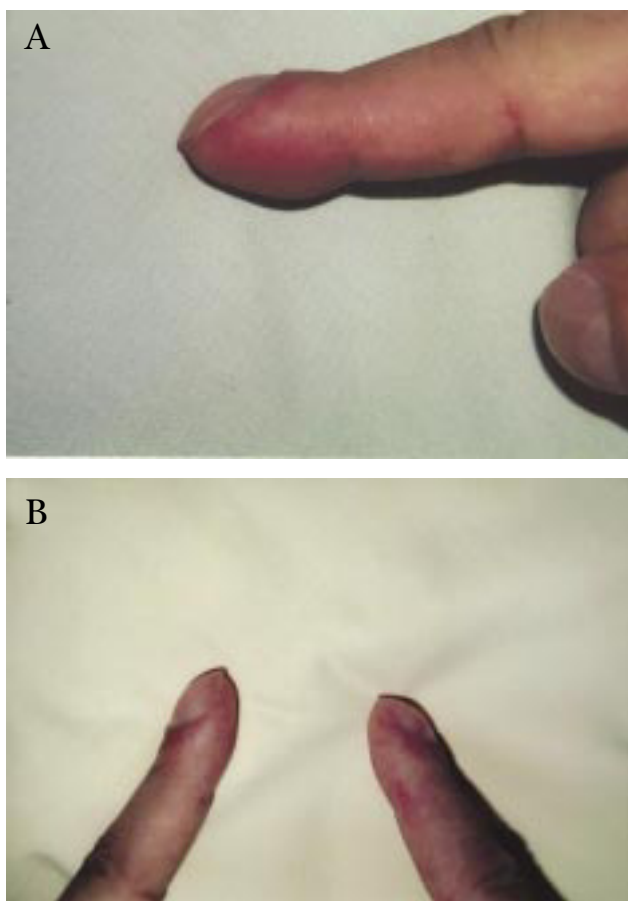


Figure 1. (A) Clubbed fingers before treatment; angle: 133°; and (B) after tumor resection and chemotherapy, clubbed fingers improve; angle: 139°.

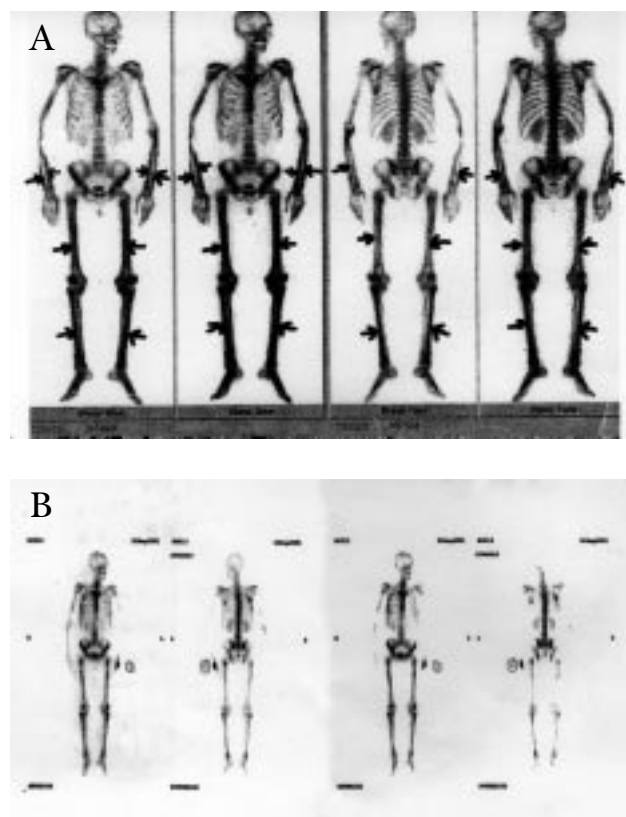


Figure 2. Tc-99m MDP (methylene diphosphonate) whole-body bone scan shows: (A) diffuse pericortical uptake throughout the long bones of all four limbs (arrows) before treatment; and (B) regression of the diffuse pericortical uptake over the long bones of all four limbs after treatment.

Long bone plain views showed no significant change, compared with previous findings. Meanwhile, the degree of clubbing of the fingers was reduced (Figure 1B) and joint pain improved.

DISCUSSION

Clubbing fingers denote an increased convexity of the nail, widening of the fingertips, and enlargement of the distal volar pad, and are diagnosed by the loss of the 15–20° between the downward curve of the proximal nail and the adjacent proximal nail fold. About 10–20% of patients with clubbing also have HOA [1]. By etiology, HOA can be classified as primary or secondary. The major conditions associated with clubbing digits and secondary HOA are shown in the Table.

The syndrome of HOA consists of clubbing, periostitis, arthropathy, and unusual skin features. The arthritis most often involves knees, ankles, wrists, and metacarpophalangeal joints and is usually associated with tenderness over adjacent bones [2,3].

Table. Major conditions associated with clubbed digits and secondary hypertrophic osteoarthropathy

Pulmonary disease
Bronchogenic carcinoma (rare with metastatic lung tumor)
Pleural neoplasm
Chronic infections other than tuberculosis
Emphysema with cor pulmonale
Mediastinal lesions
Cardiac disorders
Cyanotic congenital heart disease
Infective endocarditis
Pulmonary arteriovenous fistula
Chronic liver disease (cirrhosis)
Gastrointestinal disorders
Ulcerative colitis
Granulomatous colitis
Regional enteritis
Neoplasms
Steatorrhea of unknown cause
Hyperthyroidism
Hemoglobinopathies
Local vascular disease (unilateral clubbed fingers)

Primary HOA usually begins in childhood, while at least 90% of HOA cases in adults occur in patients who have already developed or inherited a tendency to develop a malignancy [1,4]. HOA occurs in 5–10% of patients with intrathoracic malignancies, and non-small cell lung cancer is the tumor most frequently associated with HOA. HOA is a significant presenting symptom for up to 20% of primary lung tumors [2,3].

The pathogenesis of HOA is unclear, but there are three hypotheses. The neurogenic theory is based on the observation that vagotomy and atropine can rapidly reverse the symptoms of HOA [1,2]. The humoral theory proposes that the condition is humorally mediated by substances including prostaglandins, ferritin, bradykinin, estrogen, and growth hormone [1,4]. HOA may also be caused by megakaryocytes and large platelet particles in the venous circulation that become fragmented in their passage through normal lung. Platelet–endothelial activation in the distal portion of extremities would result in the release of platelet-derived growth factor and other factors, leading to the proliferation of connective tissue and periosteum. An increased level of von Willebrand factor in the plasma of patients suffering from HOA suggests a combination of increased platelet turnover and local endothelium–platelet interactions [5,6]. The vascular component is primarily neurogenic while abnormalities in osteogenesis are humorally mediated [1].

Bone scintigraphy with Tc-99m-phosphate complexes is a sensitive method to detect HOA [2–4]. HOA shows symmetrically increased uptake along the cortical margins of the long, tubular bones, more frequently in the distal portions than the proximal parts [7]. There is a “parallel tract” or “double stripe” pattern of two different linear accumulations in the cortical portions of the bone scan. Asymmetric involvement of the extremities and irregular involvement may occur less frequently, in 17% and 15% of patients, respectively [4]. Thyroid acropachy also shows periosteal new bone formation. In our patient, normal thyroid function excluded this possibility.

Periostitis is a well-known radiographic feature of HOA and it is almost symmetric in distribution. The bones of the lower extremities are most frequently affected. Periosteal bone deposition appears initially in the proximal and distal diaphyses and metaphyses of the long tubular bones and it may extend into the

epiphyses with disease progression. Ossification of an adjacent interosseous membrane appears to be the final step in the evolution of HOA. The tibia and fibula are most commonly affected, followed by the femur and ulna. The image patterns are different between primary and secondary HOA. The most common type of periostitis observed in patients with primary HOA and congenital heart disease-associated HOA is multilayered, shaggy, and irregular, while in patients with lung cancer-associated HOA, the most common periostitis pattern is a single layer. However, the periosteal manifestations of HOA may not be related to the nature of the disease but rather to its duration or the age of the patient at onset [3].

In our case, marked improvement in joint symptoms and finger clubbing after surgery, as well as the regression in all four limbs of radioactivity uptake on bone scan suggested that the etiology of HOA in this patient was likely to be lung cancer.

REFERENCES

1. Kurzrock R, Cohen PR. Cutaneous paraneoplastic syndromes in solid tumors. *Am J Med* 1995;99:662-71.
2. Naschitz JE, Rosner I, Rozenbaum M, et al. Cancer-associated rheumatic disorders: clues to occult neoplasia. *Semin Arthritis Rheum* 1995;24:231-41.
3. Naschitz JE, Rosner I, Rozenbaum M, et al. Rheumatic syndromes: clues to occult neoplasia. *Semin Arthritis Rheum* 1999;29:43-55.
4. Uchisako H, Suga K, Tanaka N, et al. Bone scintigraphy in growth hormone-secreting pulmonary cancer and hypertrophic osteoarthropathy. *J Nuclear Med* 1995;36:822-5.
5. Wegrowski Y, Gillery P, Serpier H. Alteration of matrix macromolecule synthesis by fibroblasts from a patient with pachydermoperiostosis. *J Invest Dermatol* 1996;106:70-4.
6. Matusci-Cerinic M, Martinez-Lavin M, Rojo F, et al. Von Willebrand factor antigen in hypertrophic osteoarthropathy. *J Rheumatol* 1992;19:765-7.
7. Howell DS. Hypertrophic osteoarthropathy. In: McCarthy DJ (ed). *Arthritis and Allied Disorders*. Philadelphia: Lea & Febiger, 1979:977-82.